Cataract Surgery in Small Eyes

Richard S. Hoffman, MD

Clinical Associate Professor of Ophthalmology
Oregon Health & Science University

No Financial Interests

Anatomic Classification

- Short AC depth with short axial length
  - Nanophthalmos (simple microphthalmos)
  - Colobomatous microphthalmos
  - Complex microphthalmos
- Short AC depth with normal axial length
  - Relative anterior microphthalmos
- Normal AC depth with short axial length
  - Axial hyperopia

Nanophthalmos

Axial length less than 20.5 mm

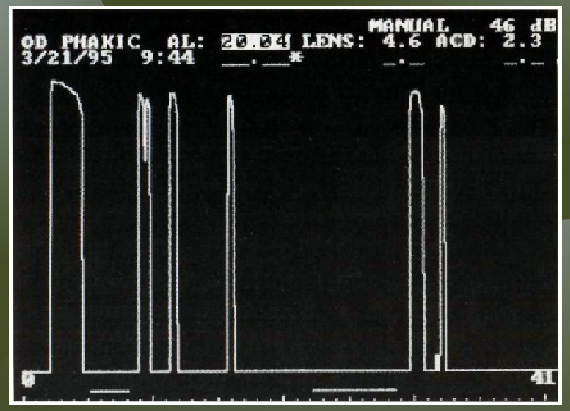

Nanophthalmos

(A) Short axial length
(B) Small cornea
(C) Shallow AC
Marked iris convexity
(D) Normal /Increased lens thickness
(E) Uveal effusions
(F) Thickened sclera
Thickened choroid

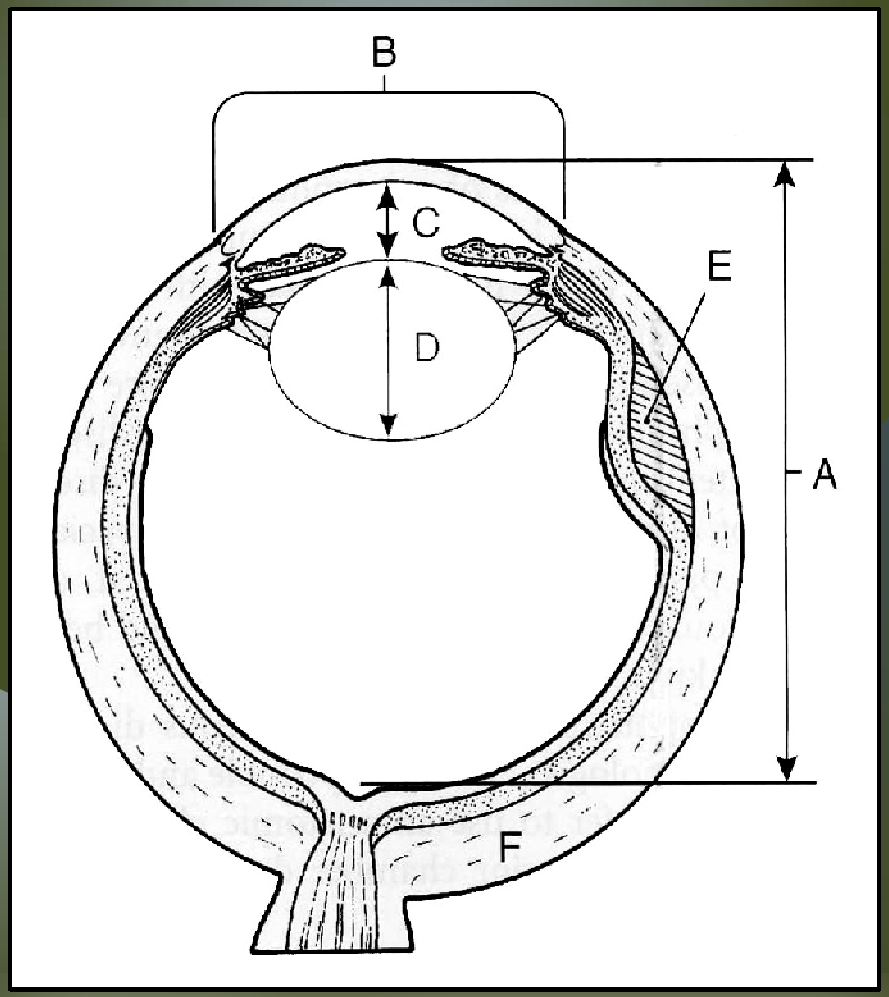

Anatomic Classification

- Short AC depth with short axial length
  - Nanophthalmos (simple microphthalmos)
  - Colobomatous microphthalmos
  - Complex microphthalmos
- Short AC depth with normal axial length
  - Relative anterior microphthalmos
- Normal AC depth with short axial length
  - Axial hyperopia

Short AC Depth / Normal Axial Length

Relative Anterior Microphthalmos

- More common than nanophthalmos
- High incidence of NAG (like nanophthalmos)
- High incidence of corneal guttata and pseudoexfoliation
- No scleral abnormalities
- No uveal effusions

Anatomic Classification

- Short AC depth with short axial length
  - Nanophthalmos (simple microphthalmos)
  - Colobomatous microphthalmos
  - Complex microphthalmos
- Short AC depth with normal axial length
  - Relative anterior microphthalmos
- Normal AC depth with short axial length
  - Axial hyperopia

Normal AC / Short Axial Length

Axial Hyperopia

- 83% of hyperopes*
- No complications
- High refractive errors
- IOL calculations



** Holladay JR. AAO 1996.*

Preoperative Assessment

Important to identify nanophthalmos preoperatively due to the potential hazards of cataract surgery

Nanophthalmos

Control Glaucoma

- Topical medications
- Laser iridotomy
- Laser gonioplasty

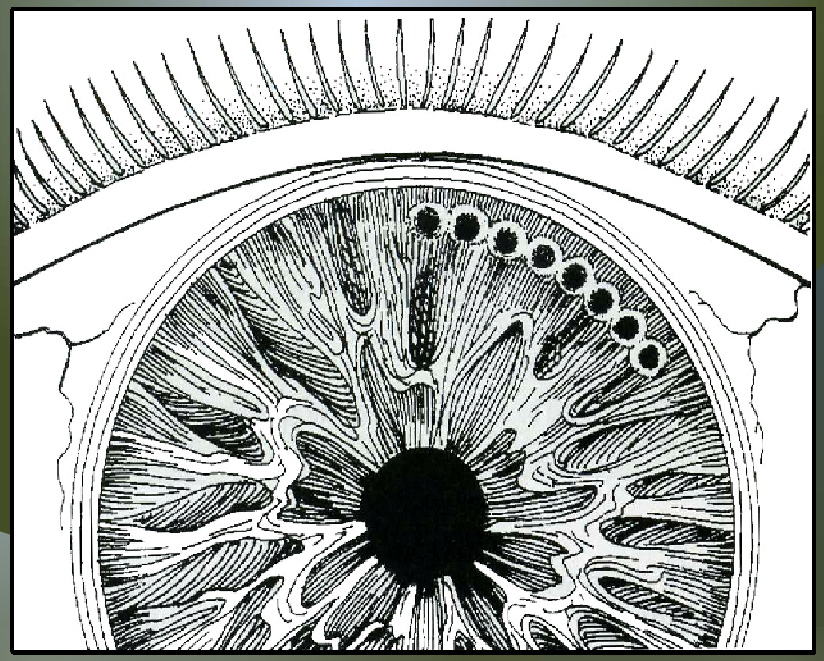

Nanophthalmos

Uveal Effusion

- Treat before or with cataract surgery
- 2 inferior sclerectomies
  - Triangular full-thickness

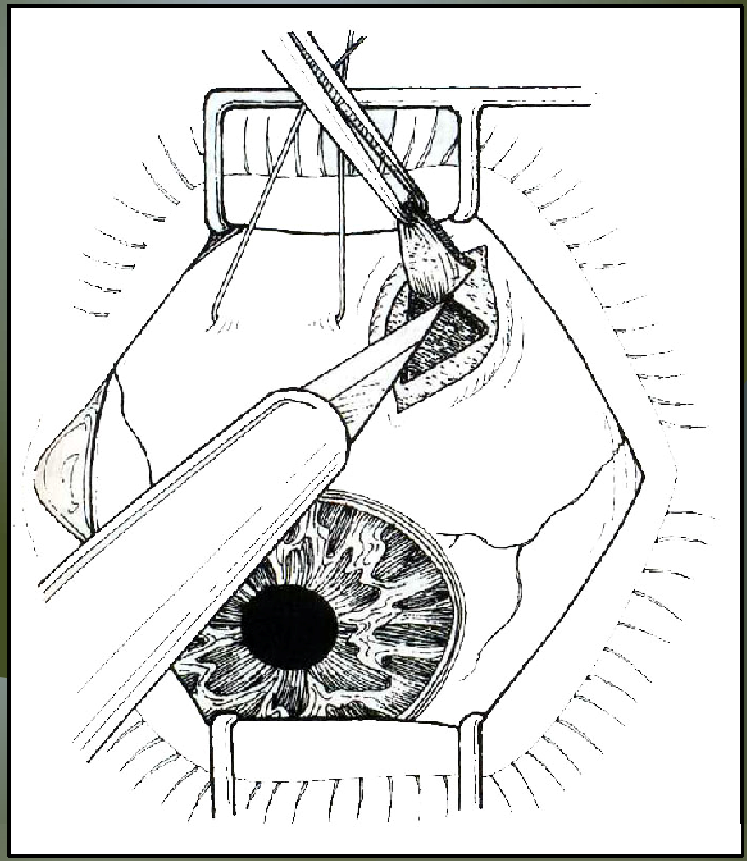

IOL Assessment

Axial Length Determination

- Critical in short eyes
- Minor error can lead to large refractive error
- Immersion biometry
- Optical biometry
  - Partial coherence interferometry

Lens Power Calculation

- Hoffer Q

- Holladay II

IOL Choice

Hyperopic Eyes

- Shallow AC depth
  - Lens powers of 30 D

- Normal AC depth
  - Lens powers of 40 – 50 D
    - Polyspeudophakia (Piggyback)

IOL Choice

- Piggyback IOLs may be better than large powered single IOL

Less spherical aberration



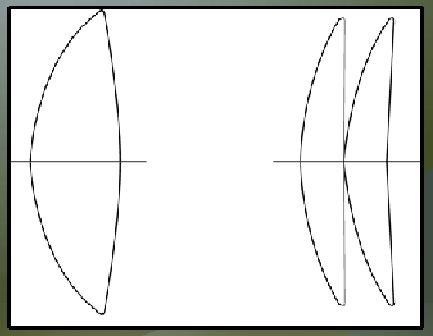

Piggyback IOLs

First report of piggyback use by Gayton in a case of microphthalmos

Gayton JL, Sanders V. J Cataract Refract Surg 1993;19:776-7

Historical Overview

Complications

- Both implants placed in the capsular bag
  - Intractable interlenticular membranes
  - Reduced visual acuity
  - Late hyperopic shift

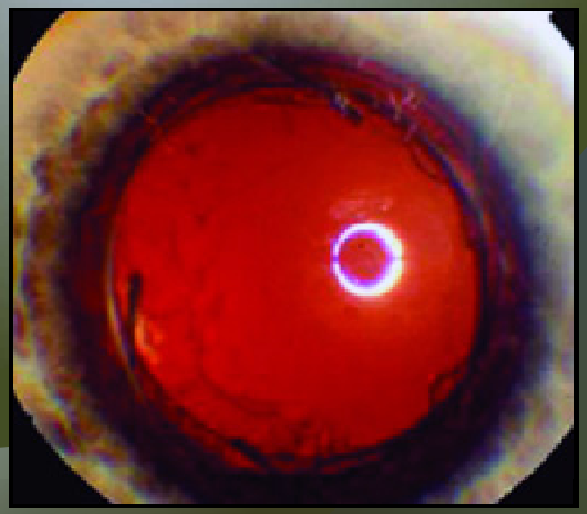

- Current recommendations
  - 1 IOL in bag / 1 IOL in sulcus
  - Simplifies possible IOL exchange

Piggyback IOL Calculations

Piggyback IOL Calculations

Easily calculated utilizing
the Holladay IOL Consultant
(R Formula)

HicSoapPro - Iol Calc Report

Report Date: **2/22/2012**

Patient: **EYE, SHORT** ID: Date of Birth: **10-Apr-1949** Sex: **Male**

Pre-Op. Data

OD	OS
Surgeon: **HOFFMAN, RICHARD S.** **02/22/2012**	Surgeon:
Refraction: **+7.75 +1.25 X 73**	Refraction:
Vertex: **12.00**	Vertex:
BCVA: **20/40**	BCVA:
UCVA:	UCVA:
K1: **40.37 @166**	
K2: **41.92 @76**	
Average K: **41.14** n: **1.3375**	
Adjusted K: **41.14**	
AL(Optical): **20.00**	Adj. AL:
Adj. AL:	Hor W-t-W:
Hor W-t-W: **12.10**	Phakic ACD:
Phakic ACD: **2.38**	Phakic Lens Th.:
Phakic Lens Th.: **0.00**	Target Ref:
Target Ref: **0.00**	Tgt Add:
Tgt Add: **0.00**	

Additional Data

OD	OS
Eye Status: **Phakic**	Eye Status:
New PC Lens: **in bag**	New PC Lens:
PreOp Pathology: **No**	PreOp Pathology:
Prev. Rk... : **No**	Prev. Rk... :
Keratoconus: **No**	Keratoconus:
Scleral Buckle: **No**	Scleral Buckle:
Silicone in Vitreous Cavity: **No**	Silicone in Vitreous Cavity:

Formula: **Holladay II**

Alcon SN60WF
Procedure: Std Phaco
PLC+ ACD(Opt): 5.51

IOL	Ref.
36.00	*NA (0.85)*
37.00	***NA (0.14)***
37.14	*NA (0.00)*
38.00	*NA (- 0.66)*
39.00	*NA (- 1.44)*

HOYA PY-60AD
Procedure: Std Phaco
PLC ACD(Opt): 5.28

IOL	Ref.
35.00	*NA (1.13)*
36.00	***NA (0.38)***
36.50	*NA (0.00)*
37.00	*NA (- 0.38)*
38.00	*NA (- 1.17)*

Formula:

Alcon MTA4UO
Procedure: Std Phaco
SRG Entrd ACD(Opt): 3.53

IOL	Ref.
31.00	*NA (0.96)*
32.00	***NA (0.13)***
32.16	*NA (0.00)*
33.00	*NA (- 0.72)*
34.00	*NA (- 1.59)*

HicSoapPro - Iol Calc Report

Report Date: **2/22/2012**

Patient: **EYE, SHORT** ID: Date of Birth: **10-Apr-1949** Sex: **Male**

Pre-Op. Data

OD

Surgeon: **HOFFMAN, RICHARD S.** **02/22/2012**

Refraction: **+7.75 +1.25 X 73**
Vertex: **12.00**
BCVA: **20/40**
UCVA:
K1: **40.37 @166**
K2: **41.92 @76**
Average K: **41.14** n: **1.3375**
Adjusted K: **41.14**

AL(Optical): **20.00**
Adj. AL:
Hor W-t-W: **12.10**
Phakic ACD: **2.38**
Phakic Lens Th.: **0.00**
Target Ref: **4.50**
Tgt Add: **0.00**

OS

Surgeon:
Refraction:
Vertex:
BCVA:
UCVA:

Adj. AL:
Hor W-t-W:
Phakic ACD:
Phakic Lens Th.:
Target Ref:
Tgt Add:

Additional Data

OD

Eye Status: **Phakic**
New PC Lens: **in bag**

PreOp Pathology: **No**
Prev. Rk... : **No**
Keratoconus: **No**
Scleral Buckle: **No**
Silicone in Vitreous Cavity: **No**

OS

Eye Status:
New PC Lens:

PreOp Pathology:
Prev. Rk... :
Keratoconus:
Scleral Buckle:
Silicone in Vitreous Cavity:

Formula: **Holladay II**

Alcon SN60WF
Procedure: Std Phaco
PLC+ ACD(Opt): 5.51

IOL	Ref.
29.50	5.31
30.00	4.99
30.75	*NA (4.50)*
31.00	***NA (4.34)***
32.00	*NA (3.67)*

HOYA PY-60AD
Procedure: Std Phaco
PLC ACD(Opt): 5.28

IOL	Ref.
29.50	4.96
30.00	**4.63**
30.19	*NA (4.50)*
31.00	*NA (3.96)*
32.00	*NA (3.28)*

Formula:

Alcon MTA4UO
Procedure: Std Phaco
SRG Entrd ACD(Opt): 3.53

IOL	Ref.
25.50	5.18
26.00	4.82
26.44	4.50
26.50	**4.45**
27.00	4.08

HicSoapPro - Iol Calc Report

Report Date: **2/22/2012**

Patient: **PIGGY, BACK** ID: Date of Birth: **10-Apr-1949** Sex: **Male**

Pre-Op. Data

OD	OS
Surgeon: **HOFFMAN, RICHARD S.** **02/22/2012**	Surgeon:
Refraction: **+5.00 +0.00 X 0**	Refraction:
Vertex: **12.00**	Vertex:
BCVA:	BCVA:
UCVA:	UCVA:
K1: **40.37 @166**	
K2: **41.92 @76**	
Average K: **41.14** n: **1.3375**	
Adjusted K: **41.14**	
AL(Optical): **20.00**	Adj. AL:
Adj. AL:	Hor W-t-W:
Hor W-t-W: **0.00**	Phakic ACD:
Phakic ACD: **2.38**	Phakic Lens Th.:
Phakic Lens Th.: **0.00**	Target Ref:
Target Ref: **0.00**	Tgt Add:
Tgt Add: **0.00**	

Additional Data

OD	OS
Eye Status: **Pseudophakic**	Eye Status:
New PC Lens:	New PC Lens:
Secondary Piggy-Back IOL	
PreOp Pathology: **No**	PreOp Pathology:
Prev. Rk... : **No**	Prev. Rk... :
Keratoconus: **No**	Keratoconus:
Scleral Buckle: **No**	Scleral Buckle:
Silicone in Vitreous Cavity: **No**	Silicone in Vitreous Cavity:
Formula: **Holladay R**	Formula:

Staar AQ-2010V
Procedure: Std Phaco
SRG Entrd ACD(Opt): 5.74

IOL	Ref.
6.00	0.84
7.00	**0.09**
7.12	- 0.00
8.00	- 0.68
9.00	- 1.47

Piggyback IOL Calculations

No Holladay IOL Consultant

Piggyback IOL

Gills Nomogram

- Underpowered Pseudophake (Hyperope)
  1. Short Eye (<21mm): Power = (1.5 x SE) + 1
  2. Average Eye (22-26mm): Power = (1.4 x SE) + 1
  3. Long Eye (>27mm): Power = (1.3 x SE) + 1

- Overpowered Pseudophake (Myope)
  1. Short Eye (<21mm): Power = (1.5 x SE) - 1
  2. Average Eye (22-26mm): Power = (1.4 x SE) - 1
  3. Long Eye (>27mm): Power = (1.3 x SE) - 1

Piggyback IOL

Nichamin Nomogram

Sulcus IOL : AQ2010V



Plus power = 1:1.5 (+5 D SE = +7.5 D IOL)

Piggyback IOL

Brown's Refractive Reasoning

0.50 D IOL power = 0.37 D at spectacle plane

Piggyback IOL Choices

AMO Sensar



- Acrylic
- 6.0 mm optic
- 13.0 mm overall length
- OptiEdge (rounded front)

  ↓ Pigment dispersion
- -10.0 to +30.0 (half-diopter steps)

Staar AQ 2010

Thin Optic Edges

- Silicone
- 6.3 mm optic (larger optic = ↓ iris capture)
- AQ2010
  - 13.5 mm length
  - +5 to +9 D (whole D steps)
  - +9.5 to 30 D (half D steps)



Raynor Sulcoflex

- Designed for sulcus placement
- Hydrophilic acrylic
- Aberration-neutral
  6.5 mm aspheric optic
- Posterior concave
  surface avoids physical contact between IOLs
- Undulating haptics with posterior 10° angulation
  - Reduced risk of Pigment Dispersion Syndrome
  - Rotational stability

Raynor Sulcoflex



Sulco*flex*® Toric

Sulco*flex*® Multifocal

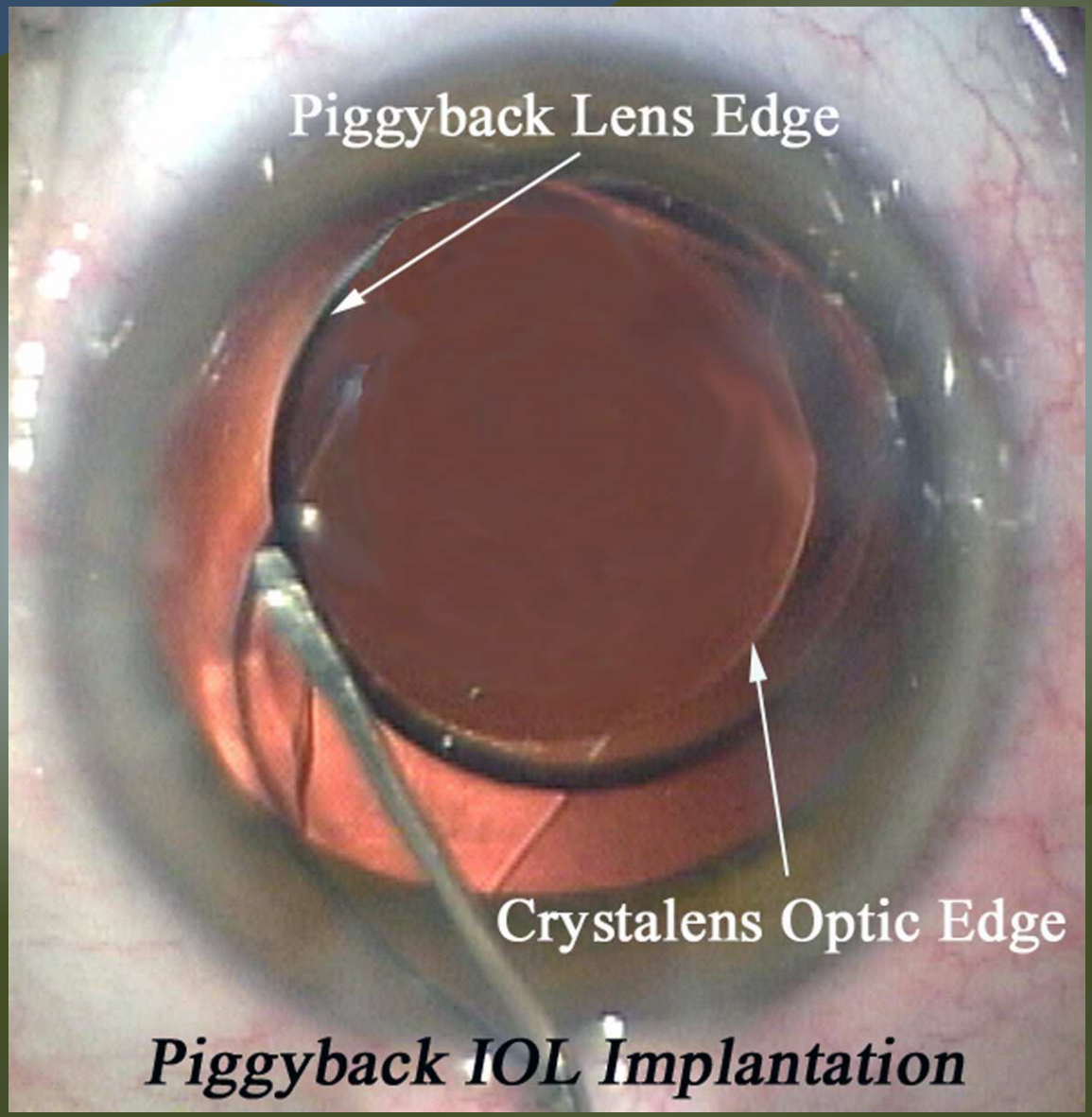

Piggyback IOL Implantation

Surgical Technique

Anesthesia

- Topical and intracameral
- Local blocks may increase posterior pressure and vortex vein congestion

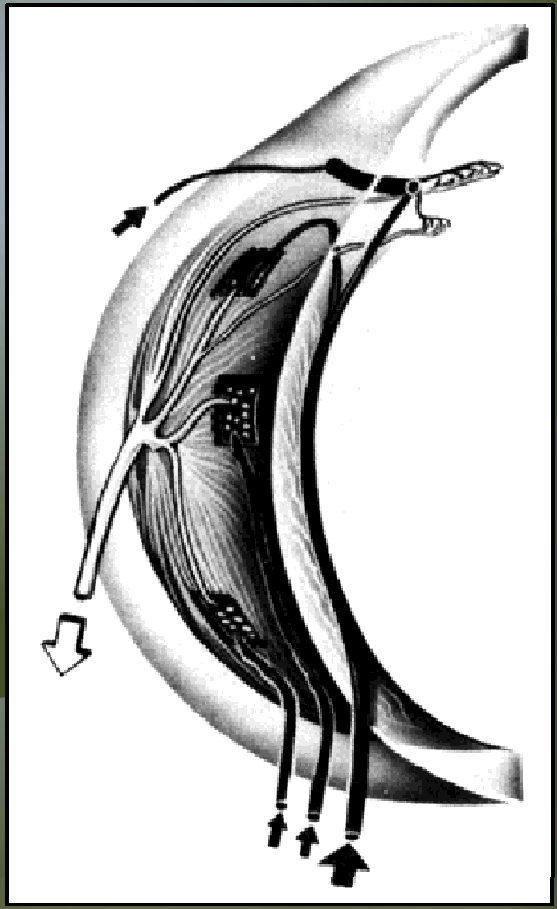

Technique

- 20% Mannitol (2 ml/kg) for IOP >25 mmHg
- Temporal clear corneal incisions
- Bimanual incisions best in small corneas
- Avoid hypotony
- Dispersive OVD
- Microincision capsulorhexis

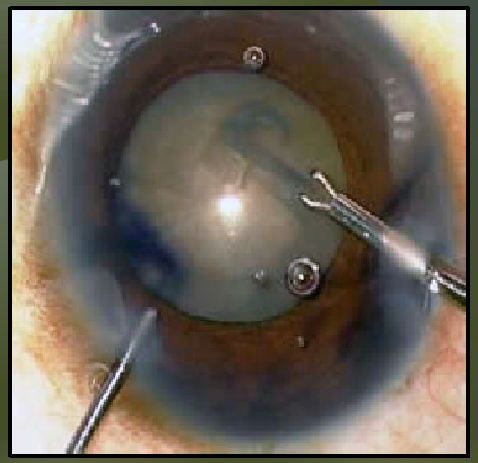

Technique

- Limited pars plana vitrectomy may be needed

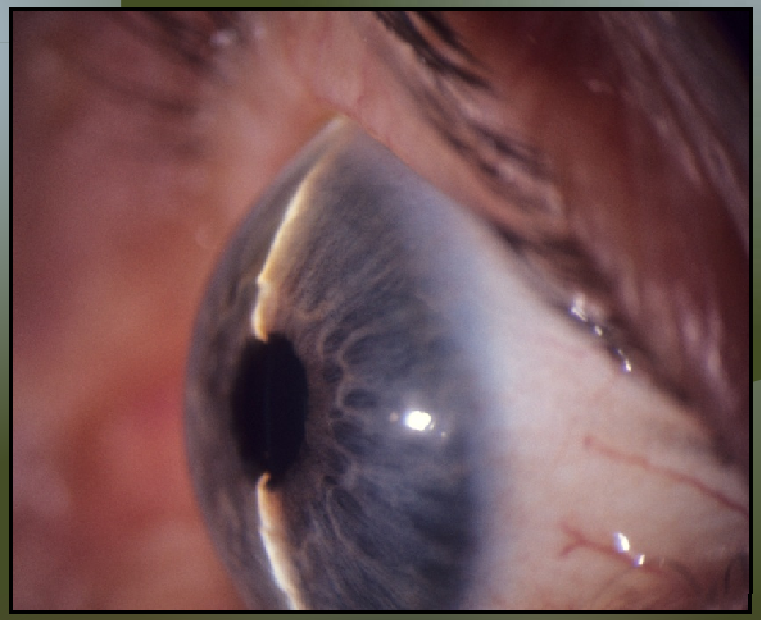

Technique

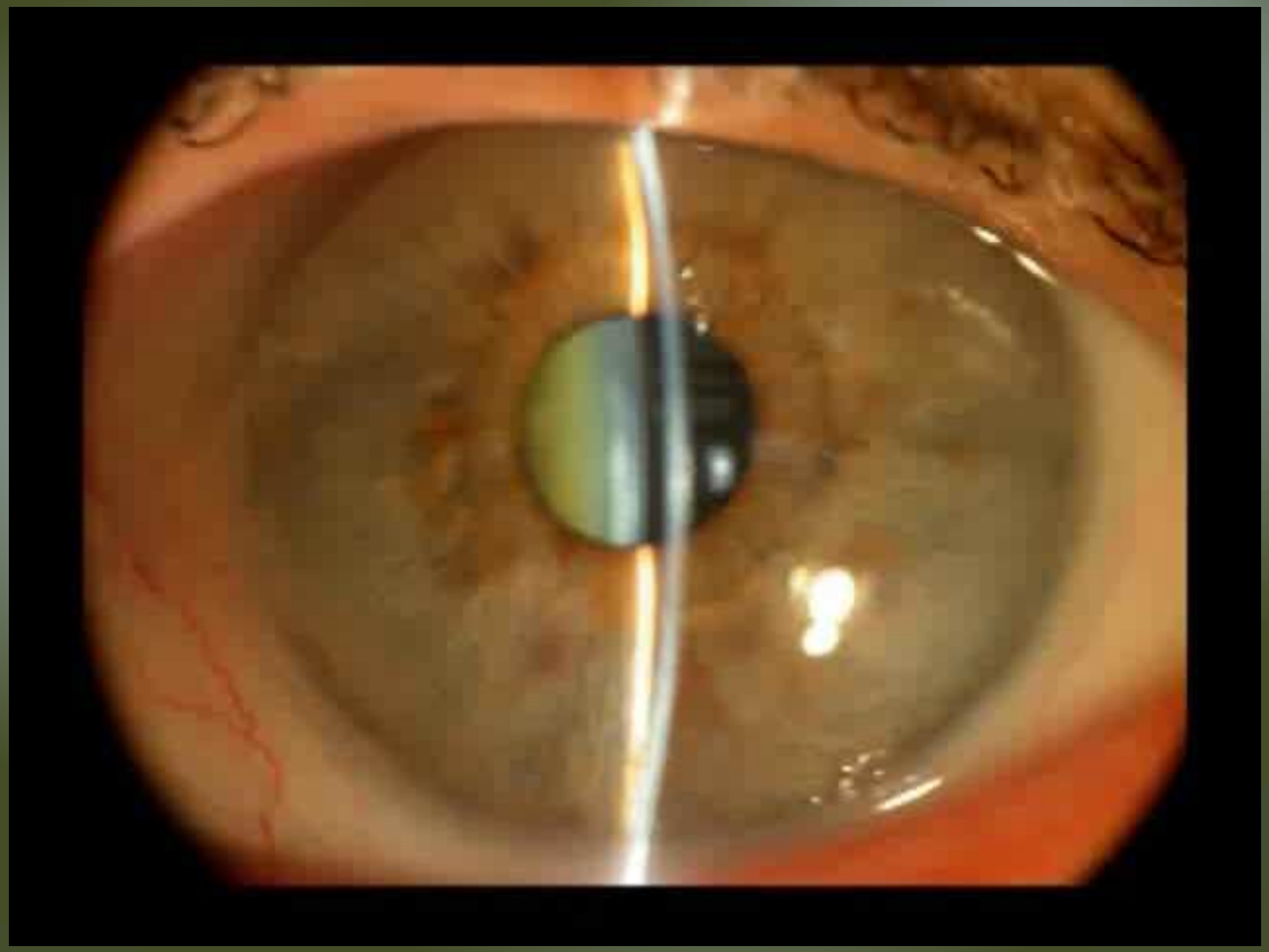

Technique

Be aware of short or non-existent pars plana in true nanophthalmos

Technique

- Risk of PC rupture increased
  - Posterior pressure
  - Weakened zonules
  - Floppy capsules
  - Thin capsules

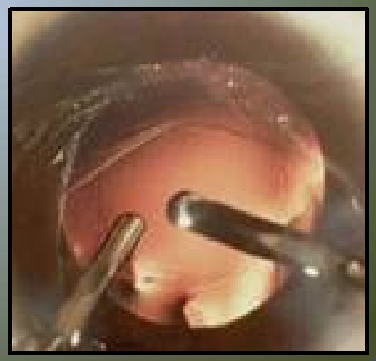

- Abort or delay surgery for sudden uveal effusion or hemorrhage
- Suture wound to prevent hypotony

Final Comments

Cataract in the Small Eye

- Most cases will be routine
- Distinguish nanophthalmos from relative anterior microphthalmos and axial hyperopia
- Hoffer Q or Holladay II
- Piggyback IOLs for > 34 D
- Maintain adequate intraoperative IOP
- Consider PPV for extremely shallow AC

Obrigado