

# The First Assistant's Role in the Management of Complications During Phacoemulsification

**T**he methods of cataract removal have changed enormously over the past 10 years. Technology and techniques are advancing at a remarkable rate. However, no matter how skilled the surgeon, how advanced the technique, or how carefully planned the procedure, complications will occasionally occur. It is essential for a competent first assistant to be fully aware of the potential complications for each surgical procedure and to know what to do when these situations occur. Preparedness to deal with unplanned events that can occur during phacoemulsification, and the management of the complications, to ensure the smooth running of the surgical procedure will now be discussed.

## Preoperative Preparedness

Our ophthalmologist teaches us that there is no procedure in ophthalmic surgery requiring a more systematized approach than phacoemulsification. Performing phacoemulsification is much like playing chess: the surgeon must plan a strategy and be thinking one or two moves ahead. Each step is dependent upon the precise and accurate




Illustration by Linda A. Warren ©1989 University of Illinois at Chicago Eye Center, ©1990 Medical Heritage Gallery, Waco, Texas.

By Mary Ellen Watson,  
COMT; and I. Howard  
Fine, MD

completion of the step prior to it.

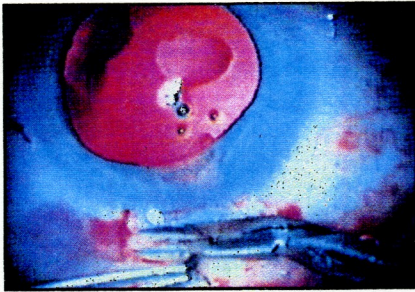
## The First Assistant

The first assistant must have already mastered the names and uses of all instruments and equipment, and will have practiced the eye/hand coordination necessary to work comfortably with the microscope or loupes. An experienced first assistant must have a positive attitude and total concentration on the procedure, the surgeon, the surgical strategy, and the surgical goals. When the surgeon and assistant are in harmony, elegance is added to the procedure. Like an orchestra conductor, the best surgeon in the world will not be able to produce the best surgical result without a coordinated team of players.

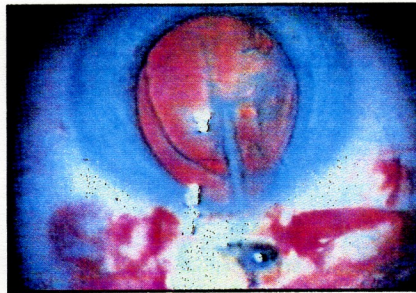
## The Patient

The preoperative evaluation will have reminded the surgeon of the surgical history of the patient's fellow eye, which might have included the occurrence of elevated postoperative intraocular pressure,

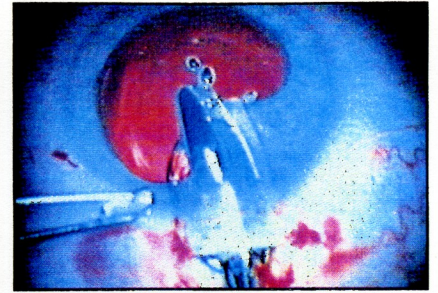




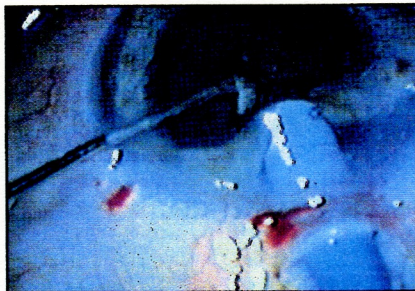
**Figure 1.** Iris prolapse is most often caused by ocular pressure, but it may also be caused by a too-large incision or if the anterior chamber is entered too far back.



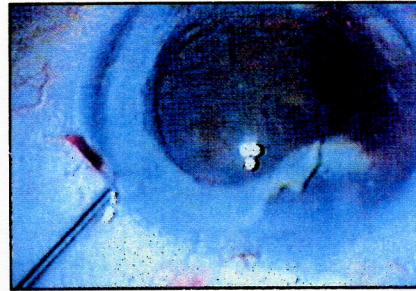
**Figure 2.** An iridectomy may be required if there is an iris prolapse or a posterior entry into the anterior chamber.



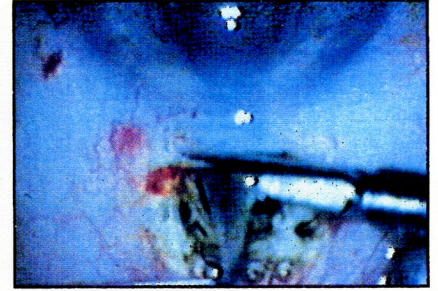
**Figure 3.** Iris prolapse or a posterior entry into the anterior chamber may also necessitate a repositing of the iris with viscoelastic and an iris spatula.



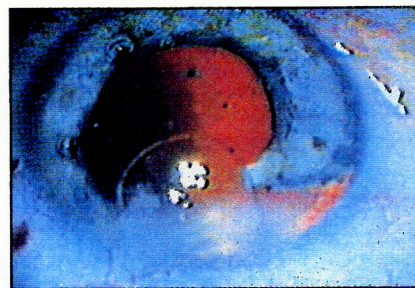
**Figure 4.** If the anterior chamber is entered too posteriorly, instrumentation inserted through that incision may cause dialysis of the iris.



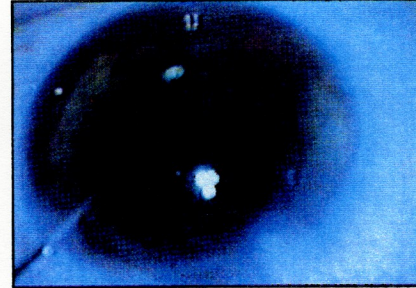
**Figure 5.** If the iris is torn, hemorrhage is often the result.



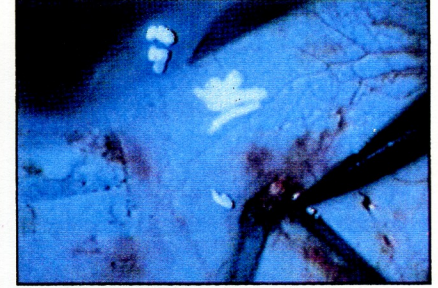
**Figure 6.** Iridectomy is an option for the management of iris dialysis.



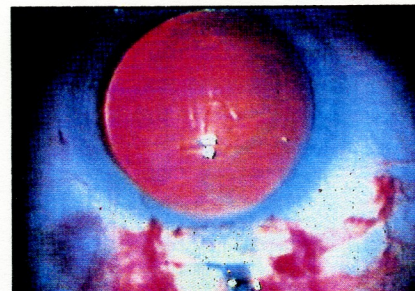
**Figure 7.** Management of iris dialysis may also necessitate the use of Sheet's glide in order to perform IOL implementation.



**Figure 8.** A rare but serious complication, choroidal effusion may occur under a variety of circumstances, but the etiology is not well-understood. Re-establishing the anterior chamber may be difficult or impossible.



**Figure 9.** Treatment of choroidal effusion consists of rapid closure of the incision with drainage of the suprachoroidal effusion through a posterior sclerotomy site.



**Figure 10.** Trailing haptics may catch on tissue or break. The first assistant should alert the surgeon to any complications.



## **Since 1967 when phacoemulsification was first performed, the incidence of complications has dramatically decreased.**

prolonged corneal edema, cystoid macular edema, or exfoliation syndrome.

Prior evaluation of the general medical condition of the patient is extremely important. The first assistant should remind the surgeon that a particular patient has physical disorders such as diabetes, hypertension, or pulmonary disease, for example, and because of the latter disorder may not be comfortable lying flat for an extended period. In this case, the surgeon will need to work with greater efficiency. Other situations include patients who may have tremor, cough, Alzheimer's disease, or may be on an anticoagulant. Awareness of these conditions may indicate that some preventative maneuvers will be necessary to avoid possible complications during the surgical procedure.

The first assistant should check the patient's head position, seeing that the chin and forehead are on a suitable plane to facilitate the surgery. If a patient has Alzheimer's disease or is likely to move, a neck brace or taping of the head may be necessary.

The anatomy and physiology of the patient's eye will not be ideal in every case. There may be deep-set eyes or inadequate exposure of the globe, in which case the surgeon may desire to perform a canthotomy. Arcus senilis should be noted because visualization will be difficult, as it interferes with the site of the incision. The surgeon should be informed preoperatively when the pupil size is inadequate. In this case, the surgeon may order more mydriatics or plan to enlarge the pupil surgically. If the eye seems to protrude, the first assistant should ask the anesthesiologist or the surgeon who gave the retrobulbar or peribulbar injection as to the amount of anesthesia given. Based on the reply, the

surgeon may decide to reapply the Honan balloon, order IV mannitol, or delay the surgery.

---

### **Intraoperative Complications**

---

Since 1967 when phacoemulsification was first performed, the incidence of complications has dramatically decreased. With state-of-the-art instrumentation, experience, and advanced surgical techniques, the management of complications has improved as well. The presentation and management of some of the most common problems and complications encountered phacoemulsification will be discussed below.

#### **Conjunctiva**

Occasionally, at the time of the anesthesia block and preoperative antibiotic injections, there may be "ballooning" of the conjunctiva (which may be relieved with digital pressure) or subconjunctival hemorrhage. The superior bridge suture may also cause a subconjunctival hemorrhage, which extends the conjunctiva over the limbus, limiting visibility within the eye. To correct this, the surgeon may choose to incise the conjunctiva to allow drainage and reduction of swelling and hemorrhage.

#### **Cornea**

It is critical that the cornea be kept wet at all times to prevent drying and epithelial

haze, which will limit the surgeon's visibility. If a corneal abrasion occurs during surgery, extra attention must be given to keep the cornea wet to maintain visibility.

Descemet's stripping almost always occurs as the result of forceful and improper introduction of an instrument or lens through the incision into the anterior chamber. Gentle manipulation or enlarging the incision will prevent this in most cases. By careful attention to the operation, the first assistant will be able to note its occurrence. If this stripping occurs, it can be managed by replacing the flap in its bed and instilling viscoelastic prior to any subsequent entry into the anterior chamber. During subsequent steps of the procedure, the first assistant can remind the surgeon that a flap is present. The surgeon may want to inject an air bubble at the end of the case. The air bubble will rise when the patient is in the upright position, tamponading the flap.

#### **Anterior Chamber**

The surgery takes place in the anterior chamber, which is approximately 3 mm in depth. If an instrument touches the corneal endothelium above or the posterior capsule below, complications may occur. The first assistant must develop a constant sense of awareness of the normal anterior chamber depth. Signs of shallowing include: the cornea tends to collapse, the anterior chamber appears crowded, the nucleus or posterior capsule comes forward, or the iris tends to prolapse.

When shallowing of the anterior chamber is recognized, the surgeon will determine if the eye is soft or hard. If the eye is soft, the first assistant may check the bridge suture, lid speculum, basic salt solution (BSS) bottle height, and pump speed. If the eye is hard, causes may be any of the above

## **The first assistant must develop a constant sense of awareness of the normal anterior chamber depth.**



## Successful management of a complication is enhanced by a combination of surgical skill, good judgement, and a well-trained, highly motivated first assistant.

but may also include such severe complications as choroidal effusion or hemorrhage. In this case, the surgeon will stop ultrasound and address this problem.

When anterior chamber hemorrhage occurs, the surgeon will control it by irrigation and aspiration or by tamponade with a viscoelastic. The first assistant and surgeon should note whether the hemorrhage is spreading or has stopped, particularly after the incision has been closed.

### Iris

Stromal damage or iris chafing is most often caused when the protruding portion of the "phaco" needle touches the iris during phacoemulsification. Iris prolapse usually occurs from ocular pressure, but may also occur when the incision is too large or when the anterior chamber was entered too far back (Figure 1). A corneal or scleral suture can reduce an oversized incision appropriately. An iris prolapse and a posterior entry into the anterior chamber may require the surgeon to perform an iridectomy (Figure 2), reposit the iris with viscoelastic and an iris spatula (Figure 3), or close the incision and make a new entry into the anterior chamber (either at the limbus or at another posterior scleral meridian).

Dialysis of the iris (Figure 4) can result from instrumentation of the anterior chamber through an incision that enters the anterior chamber too posteriorly. Other causes of iris dialysis include inadequate visualization, bevel-up entry with the phaco

tip, or a careless maneuver with the second handpiece. Hemorrhage often follows the iris tearing (Figure 5). Management of a dialysis complication may include iridectomy (Figure 6), repair of the iridodialysis with a McCannel suture, or protection of the iridodialysis with a Sheets glide (Figure 7).

### Nucleus/Cortex

Turbulent movements of nuclear remnants can cause endothelial damage as well as postoperative inflammation. The first assistant should help the surgeon watch for small particles in the angle near the side port or at the 12 o'clock meridian. These are very difficult to see and it is important that they be removed. It is rare, however, for small amounts of retained cortex to create trouble. A good-natured reminder by the assistant that a posterior capsular tear is much more trouble than a little retained cortex may be received as a welcome relief by the surgeon in his frustrating attempt to remove every last bit of cortex.

### Posterior Capsule

The posterior capsule is very delicate. Causes of posterior capsule rupture include occlusion of the ultrasound tip in emulsification or aspiration, tears caused by a sharp nuclear edge, or perforation by an instrument in the eye. During phacoemulsification, the first assistant should watch for sudden signs of deepening of the anterior chamber or failure of the phaco tip to cut, and a lack of rebound when the nucleus is displaced. These are all intraoperative signs of posterior capsular rupture, and the first assistant should be

## Ophthalmic Surgery

# KEY POINTS

**Watson ME, Fine IH.**  
**The First Assistant's**  
**Role in the Management**  
**of Complications Dur-**  
**ing Phacoemulsification.**  
**Today's OR Nurse. 1991;**  
**13(11):17-21.**

1. Every surgeon who performs phacoemulsification will encounter complications. Successful management of complications is enhanced by a combination of surgical skill, good judgment, and a well-trained, highly motivated first assistant.
2. The first assistant must have already mastered the names and uses of all instruments and equipment, and will have practiced the eye/hand coordination necessary to work comfortably with microscopes and loupes. A positive attitude and total concentration on the procedure and the surgeon is imperative.
3. A complete understanding of the management of the most common complications will enable the assistant to begin setting the stage to manage a complication during the anticipatory phase.



ready with viscoelastic and a second hand-piece should any of these things occur. If it is small tear, the surgeon may carefully continue with the planned procedure. If the tear is large or vitreous is present, the surgeon may proceed with modifications in his usual technique (the use of a Sheets glide, for example). If vitreous has come forward, the assistant should be ready for a vitrectomy and the possibility of converting to an extracapsular procedure.

#### Vitreous

The incidence of vitreous loss is quite small, but when it does occur, it must be managed with utmost care and consideration. When vitreous is present, the surgeon will notice that aspiration seems less efficient, the phaco tip will not cut, and the nucleus seems harder to control. There may be peaking of the pupil, or nuclear particles may drift downward. The surgeon may stop ultrasound or proceed with a bimanual vitrectomy, and may enlarge the incision and proceed to an extracapsular technique.

#### Choroid

Choroidal effusion is a rare but very serious complication (Figure 8). This may occur under a variety of circumstances, but the etiology is not well understood. The eye becomes very hard, and the anterior chamber shallows and will not hold BSS, air, or viscoelastic. Treatment consists of rapid closure of the incision with drainage of the suprachoroidal effusion through a posterior sclerotomy site (Figure 9). The procedure may be completed immediately following drainage or a day or two later.

#### Insertion of the Lens

The first assistant should verify the lens power both prior to surgery and at the time of insertion, as well as inspect, clean/irrigate, and prepare the lens for insertion. On rare occasions, the haptics may be of unequal length, bent, or broken and the lens must be replaced. The assistant should watch the trailing haptic and alert the surgeon should it catch on tissue or break

(Figure 10). If the surgeon has difficulty positioning the lens, an extra pair of eyes will help observe placement of the haptics.

#### Conclusion

Every surgeon who performs phacoemulsification will at times encounter complications. Successful management of a complication is enhanced by a combination of surgical skill, good judgment, and a well-trained, highly motivated first assistant.

#### ABOUT THE AUTHORS

Mary Ellen Watson, COMT, is First Assistant; I. Howard Fine, MD, is Clinical Assistant Professor of Ophthalmology, Oregon Health Sciences University, Portland.

Address correspondence to Mary Ellen Watson, COMT, 1550 Oak Street, Suite 5, Eugene, OR 97401-7701.

## This is what it feels like to have asthma.

**Try breathing through a thin straw. With an asthma attack it's a fight for every breath you draw.**

Asthma is a serious lung disease that can affect children and adults at any time. An attack can be triggered by such diverse causes as cold air, pets, tobacco smoke, dust, and stress. The American Lung Association® is helping people control asthma so they can lead happy, normal, active lives.



**It's a matter of life and breath®**

**AMERICAN  LUNG ASSOCIATION®**  
The Christmas Seal People®

Space contributed by the publisher as a public service.