

---

# Suture fixation of a foldable acrylic intraocular lens for ectopia lentis

Mark Packer, MD, I. Howard Fine, MD, Richard S. Hoffman, MD

## ABSTRACT

A 5-year-old boy with severe ectopia lentis had bilateral lensectomy and suture fixation of a foldable acrylic intraocular lens (IOL) through a 3.0 mm clear corneal incision. Sodium hyaluronate (Healon GV®) enhanced stability of the crystalline lens during aspiration and maintenance of the anterior chamber during passage of the needles through the ciliary sulcus. The haptic design of the single-piece AcrySof® (Alcon) IOL permitted secure fixation of the suture to the haptic. The patient experienced rapid visual rehabilitation, achieving an uncorrected visual acuity of 20/40 in both eyes. *J Cataract Refract Surg* 2002; 28: 182–185 © 2002 ASCRS and ESCRS

Ectopia lentis can exist in isolation or in association with a variety of ocular and systemic conditions. Management options include prescription of the best optical correction, a trial of mydriasis if the lens equator intersects the pupil, and lensectomy. Following lensectomy, options for rehabilitation include aphakic spectacles (if bilateral), contact lens correction, and intraocular lens (IOL) implantation.

Surgical management has been controversial because of the high complication rate of earlier techniques. Jensen and Cross<sup>1</sup> report early postoperative complications including vitreous loss, hyphema, and corneal edema in over half their series and retinal detachment in 1 of 5 cases. Subsequent authors<sup>2</sup> recommend lensectomy and anterior vitrectomy to reduce the potential for vitreoretinal traction. A recent series of 21 eyes having lensectomy and sulcus fixation of a 7.0 mm poly(methyl methacrylate) (PMMA) IOL reports a follow-up be-

tween 9 and 33 months.<sup>3</sup> No vision-threatening complications occurred.

Lam et al.<sup>4</sup> recently reported scleral fixation of a capsular tension ring for severe ectopia lentis. A 7.0 mm PMMA lens was implanted in both eyes of 1 patient. However, the procedure had to be abandoned in the first eye in favor of scleral fixation of the IOL because “the equatorial region of the capsule. . . splayed open, most likely because of the compromised integrity of the capsule from the needle puncture.” The outcomes in the 2 eyes were comparable.

While these results indicate an improvement over earlier techniques, the implantation of a single-piece PMMA IOL requires a large corneoscleral incision with its resultant astigmatism. Suture fixation of foldable IOLs has proved difficult not only because of the lack of an adequate location on the haptic for affixing the suture but also because of possible tilt, rotation, and decentration. The unique design characteristics of the Alcon single-piece acrylic lens (AcrySof®, SA30AL) make it possible to securely fixate a 10-0 polypropylene (Prolene®) suture to the haptic just proximal to the terminal knob. The flexibility of the SA30AL haptic may also allow growth of the eye without placing increased stress on the fixation suture. Nevertheless, long-term stability of a suture-fixated IOL remains a concern, particularly in the pediatric population. This report describes a tech-

---

*Accepted for publication March 22, 2001.*

*From a private practice, Eugene, Oregon, USA.*

*Presented in part at the XVIIIth Congress of the European Society of Cataract & Refractive Surgeons, Brussels, Belgium, September 2000.*

*None of the authors has a financial interest in any product mentioned.*

*Reprint requests to Mark Packer, MD, 1550 Oak Street, Suite 5, Eugene, Oregon 97401, USA.*

nique for sulcus fixation of a foldable single-piece acrylic IOL through a 3.0 mm clear corneal incision.

## Case Report

A 5-year-old boy was referred for decreased visual acuity secondary to bilateral ectopia lentis. The medical history included attention-deficit hyperactivity disorder. The best corrected visual acuity was 20/40 in the right eye and 20/60 in the left, with corrections of  $-24.0 +13.5 \times 60$  and  $-20.5 +10.5 \times 120$ , respectively. Slitlamp examination revealed bilateral superonasal subluxation of the crystalline lens with the equator of the lens visible within the pupil. The pupil diameter was 4.5 mm in dim room illumination. Intraocular pressure (IOP) was within normal limits. Examination of the lenses following pupillary dilation revealed no evidence of cataract. Examination with the indirect ophthalmoscope was unremarkable. After informed consent was obtained from the patient's mother, the patient was scheduled for lensectomy and suture fixation of a posterior chamber IOL in the right eye and then in the left eye approximately 6 weeks later.

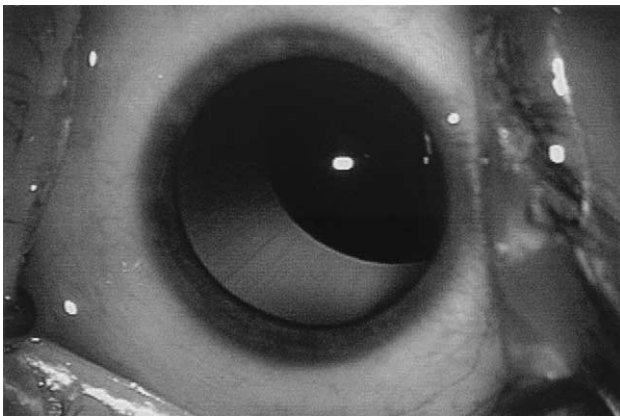
Biometry was obtained with ultrasonic axial length measurements and keratometry as well as with the Zeiss IOLMaster (right eye: K1,  $39.80 \times 25$  and K2,  $42.72 \times 115$ ; axial length, 23.32 mm; horizontal white-to-white, 12.0 mm; left eye: K1,  $40.32 \times 148$  and K2,  $43.32 \times 58$ ; axial length, 22.75 mm; horizontal white-to-white, 12.0 mm). The Holladay 2 formula predicted a postoperative refraction of +0.06 in the right eye with a 23.0 diopter (D) single-piece AcrySof SA30AL IOL and of -0.11 in the left eye with a 24.5 D single-piece AcrySof SA30AL IOL (A-constant 118.4, overall diameter 12.5 mm, optic diameter 5.5 mm).

The same procedure was performed in each eye (Figure 1). Following a limited conjunctival peritomy, triangular limbus-based scleral flaps were constructed 180 degrees apart with a Grieshaber microcrescent knife. Sodium hyaluronate

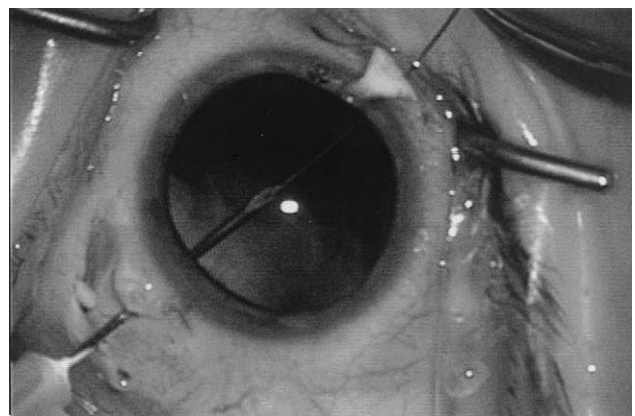
(Healon GV®) was introduced into the anterior chamber via a paracentesis incision. Additional viscoelastic material was placed through the zonule posterior to the subluxated lens to stabilize the lens and tamponade the vitreous body. A 3.0 mm clear corneal incision was fashioned with a Rhein 3-D diamond knife (right eye) or Accutome 3.0 mm diamond knife (left eye). The lens capsule was incised with a curved needle cystotome. The lens substance was aspirated using a Mentor (right eye) or AMO Diplomax (left eye) vitrectomy instrument with maximum vacuum and a flow rate of 24 cc/min. The bottle height was titrated based on observed irrigation at the tip. The remaining lens capsule was removed with the vitrector at 400 cuts/min and 500 mm Hg maximum vacuum. The anterior chamber was again filled with Healon GV.

One arm of a double-armed 10-0 Prolene suture on a long straight needle (Ethicon, STC-6) was passed ab externo under the scleral flap 1.0 mm posterior to the limbus and then via the ciliary sulcus into the posterior chamber. A 27-gauge needle was passed in a similar fashion under the opposite scleral flap and mated with the needle in the posterior chamber (Figure 2). The 27-gauge needle was then withdrawn, carrying the 10-0 Prolene suture with it. This suture now bridged the posterior chamber. It was withdrawn from the corneal incision with a Lester hook and cut. The AcrySof lens was then folded and held in the insertion forceps while Prolene was tied to each haptic. The suture was applied to the haptic after folding to avoid potential entanglement of the stitch in the folding forceps. The narrow neck of the haptic just proximal to the terminal knob presented an ideal location for affixing the suture. The IOL was then introduced into the eye and rotated into position (Figure 3). It was centered by adjusting the tension on the suture.

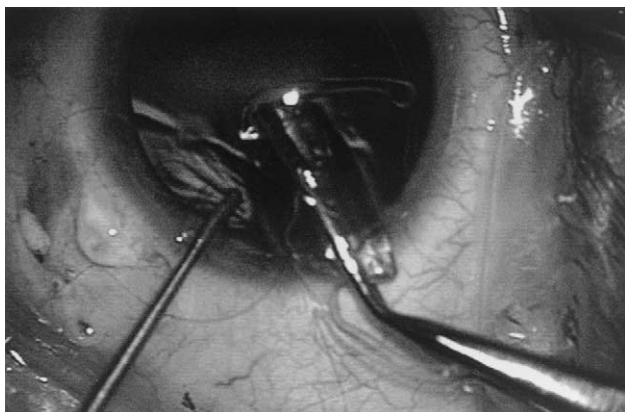
Once the IOL was adequately centered, each arm of the suture was passed through episclera and the needle was cut off. The suture tail was tied to the resulting loop so the knot was placed under the scleral flap. Each flap was then sutured with 10-0 nylon. After the viscoelastic material was removed with



**Figure 1.** (Packer) Surgeon's temporal view of the left eye showing superonasal displacement of the crystalline lens.



**Figure 2.** (Packer) A 10-0 Prolene STC-6 needle is mated in the posterior chamber with a 27-gauge needle.



**Figure 3.** (Packer) A single-piece AcrySof IOL is inserted through the clear corneal incision. The 10-0 Prolene can be seen affixed to the neck of the leading haptic.

the vitrectomy instrument, single interrupted stitches of 10-0 polyglactin 910 (Vicryl®) were used to close the corneal incision and the conjunctiva. Postoperatively, the eye was treated with combination antibiotic/antiinflammatory ointment and atropine ointment.

On the first postoperative day, the visual acuity was 20/200 in the right eye without correction. Slitlamp examination revealed 1+ microcystic edema of the cornea secondary to elevated IOP. The IOL was noted to be well centered. The IOP spike was thought to be due to residual viscoelastic material. By 2 weeks, the visual acuity was 20/40 without correction (by tumbling E's). The atropine was discontinued, and the pupil returned to its preoperative dimensions.

The first day after surgery in the left eye, the visual acuity was 20/50<sup>-3</sup> without correction (by tumbling E's). The cornea was clear and the IOL centered and stable. At 2 weeks, the uncorrected visual acuity (UCVA) had improved to 20/40 (by tumbling E's). Retinoscopy demonstrated a postoperative refraction of -0.50 sphere in the right eye and -0.75 sphere in the left.

At 4 months in the right eye and 2 months in the left eye, the UCVA was 20/40 (by tumbling E's). The conjunctiva was quiet and well healed over the scleral flaps. The corneas were clear and the chambers deep and quiet. The IOLs were positioned centrally in the posterior chambers.

## Discussion

Suture fixation of a foldable posterior chamber IOL represents an acceptable alternative for the rehabilitation of vision after lensectomy for ectopia lentis. The reduction in induced astigmatism from the levels occurring with a 7.0 mm corneoscleral incision represents an improvement in technique, allowing rapid achievement of good postoperative UCVA. The unique haptic design of

the single-piece AcrySof lens allows easy and secure fixation of the Prolene suture to the IOL.

The reduction in optic size from 7.0 to 5.5 mm may be of concern in the presence of a large pupil. In this patient, the preoperative pupil diameter of 4.5 mm reassured us that the optic would be well tolerated. Unwanted visual phenomena may result if the pupil is larger than the optic. Also, subluxation of the IOL through the pupil has been described with a 7.0 mm optic.<sup>3</sup> In the series of 21 eyes reported by Zetterström and coauthors,<sup>3</sup> 2 developed subluxation of the IOL into the anterior chamber. The subluxation of the IOL may have been related to pupil diameter, a floppy iris, asymmetric suture configuration, or IOL tilt. Preoperative evaluation of the pupil and iris may be important in selecting the IOL design and placement. The greater flexibility of the SA30AL IOL haptics may produce a longer arc of contact between the haptic and the ciliary sulcus, improving the stability of the IOL. On the other hand, the increased flexibility at the haptic-optic junction raises concerns about possible tilt of the optic despite stable positioning of the haptics.

The high zero-shear viscosity and mean relaxation time of Healon GV permit maintenance of a comfortable working space in the relatively less rigid and smaller pediatric eye.<sup>5</sup> These qualities facilitate stability of the ectopic lens during lensectomy and protect the iris and cornea during passage of the 10-0 Prolene and 27-gauge needles. Future availability of sodium hyaluronate 2.3% (Healon®5) may offer a further improvement in this technique.

The life span of 10-0 Prolene is another concern in the suture fixation of an IOL (or modified capsular tension ring), particularly in the pediatric age group. Mowbray and coauthors<sup>6</sup> suggest a useful lifetime of Prolene in the anterior chamber based on in vitro data of between 53 and 75 years, depending on ambient ultraviolet radiation. However, Jongebloed and Worst<sup>7</sup> demonstrate degradative changes with scanning electron microscopy in a Prolene suture removed from the eye of a Dutch patient after 6.5 years.

Suture wick endophthalmitis presents a special risk in suture fixation of IOLs.<sup>8</sup> However, protecting the exposed suture under a scleral flap that is then protected under the conjunctiva likely helps to reduce this risk. Similarly, rotating the knots under the sclera represents an alternative safe technique.<sup>9</sup>

Long-term stability of the suture-fixated IOL remains a concern. Currently, no foldable IOL that permits 4-point fixation via haptic eyelets is available. Furthermore, maintenance of the bicameral eye by preserving the lens capsule and suture fixation of a modified capsular tension ring may prove advantageous in the long term.

In summary, the unique design characteristics of the single-piece AcrySof IOL make possible the suture fixation of a foldable posterior chamber IOL through a small clear corneal incision with excellent visual results. Longer follow-up is needed to ascertain the stability of this suture-fixated IOL over time.

### References

1. Jensen AD, Cross HE. Surgical treatment of dislocated lenses in the Marfan syndrome and homocystinuria. *Trans Am Acad Ophthalmol Otolaryngol* 1972; 76:1491–1499
2. Halpert M, BenEzra D. Surgery of the hereditary subluxated lens in children. *Ophthalmology* 1996; 103:681–686
3. Zetterström C, Lundvall A, Weeber H Jr, Jeeves M. Sulcus fixation without capsular support in children. *J Cataract Refract Surg* 1999; 25:776–781
4. Lam DSC, Young AL, Leung ATS, et al. Scleral fixation of a capsular tension ring for severe ectopia lentis. *J Cataract Refract Surg* 2000; 26:609–612
5. Dick HB, Schwenn O. *Viscoelastics in Ophthalmic Surgery*. Berlin, Springer-Verlag, 2000
6. Mowbray SL, Chang S-H, Casella JF. Estimation of the useful lifetime of polypropylene fiber in the anterior chamber. *Am Intra-Ocular Implant Soc J* 1983; 9:143–147
7. Jongebloed WL, Worst JFG. Degradation of polypropylene in the human eye: a SEM-study. *Doc Ophthalmol* 1986; 64:143–152
8. Heilskov T, Joondeph BC, Olsen KR, Blankenship GW. Late endophthalmitis after transscleral fixation of a posterior chamber intraocular lens. *Arch Ophthalmol* 1989; 107:1427
9. Lewis JS. Sulcus fixation without flaps. *Ophthalmology* 1993; 100:1346–1350