

FOCAL POINTS

American Academy of Ophthalmology

CLINICAL MODULES FOR OPHTHALMOLOGISTS

VOLUME XXV NUMBER 6

JUNE 2007 (SECTION 3 OF 3)

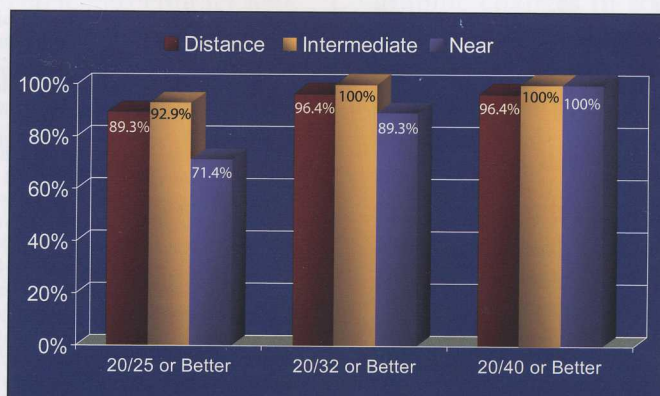


Refractive Lens Exchange

Mark Packer, MD, FACS

I. Howard Fine, MD

Richard S. Hoffman, MD



Consultants

Elizabeth A. Davis, MD, FACS
Audrey R. Talley-Rostov, MD

Reviewers and Contributing Editors

Editor for Cataract Surgery:
Thomas L. Beardsley, MD

*Basic and Clinical Science
Course Faculty, Section 11:*
James C. Bobrow, MD

*Practicing Ophthalmologists
Advisory Committee for Education:*
John Berestka, MD

Refractive Lens Exchange

Introduction

Patient Selection Criteria

- Age
- Presbyopia
- Myopia
- Personality and Lifestyle
- Outcomes

Preoperative Evaluation

- Biometry
- Keratometry and Intraocular Lens Power Calculation

Surgical Technique

Intraocular Lens Selection

- Monofocal Lenses
- Multifocal Lenses
- Accommodative Intraocular Lenses

Conclusion

Clinicians' Corner

Claiming CME Credit

Academy members: To claim *Focal Points* CME credits, visit the Academy web site and access CME Central (<http://www.aao.org/education/cme>) to view and print your Academy transcript and report CME credit you have earned. You can claim up to two AMA PRA Category 1 Credits™ per module. This will give you a maximum of 24 credits for the 2007 subscription year. **Non-Academy members:** For assistance please send an e-mail to customer_service@aao.org or a fax to (415) 561-8575.

Financial Disclosures

The authors and consultants disclose the following financial relationships. **Mark Packer, MD, FACS:** (C) Advanced Medical Optics, Advanced Vision Science, Bausch & Lomb, Carl Zeiss Meditec, Carl Zeiss Surgical GmbH, Celgene Corporation, Ethicon, Gerson Lehman Group, iScience Surgical Corporation, Johnson & Johnson Vision Care (Vistakon Division), Leerink Swann & Company, Medtronic Xomed, Visiogen (stock options), Vision-Care, and WaveTec Vision Systems. (L) Eyeonics, STAAR Surgical, Alcon Laboratories, and Endo Optiks. **I. Howard Fine, MD:** (C) Advanced Medical Optics, Bausch & Lomb, iScience, Carl Zeiss Meditec, and Omeros. (L) Alcon Laboratories, Eyeonics, Rayner Intraocular Lenses, and STAAR Surgical. **Elizabeth A. Davis, MD, FACS:** (C) Advanced Medical Optics, Bausch & Lomb, STAAR Surgical, IntraLase, and ISTA. (L) Allergan and Refractec. **Audrey R. Talley-Rostov, MD:** (C) Addition Technology, Allergan, and Visiogen. The other contributors and reviewers state that they have no significant financial or other relationship with the manufacturer of any commercial product or provider of any commercial service discussed in the material they contributed to this publication or with the manufacturer or provider of any competing product or service. C = consultant fee, paid advisory boards, or fees for attending a meeting. L = lecture fees (honoraria), travel fees, or reimbursements when speaking at the invitation of a commercial entity.

Focal Points Editorial Review Board

Dennis M. Marcus, MD, Augusta, GA: Editor-in-Chief, *Retina & Vitreous* • Thomas L. Beardsley, MD, Asheville, NC: *Cataract* • Keith D. Carter, MD, Iowa City, IA: *Oculoplastic, Lacrimal, & Orbital Surgery* • William S. Clifford, MD, Garden City, KS: *Glaucoma Surgery*; Liaison for *Practicing Ophthalmologists Advisory Committee for Education* • Anil D. Patel, MD, Oklahoma City, OK: *Neuro-Ophthalmology* • George A. Stern, MD, Missoula, MT: *Cornea, External Disease & Refractive Surgery*; *Optics & Refraction* • C. Gail Summers, MD, Minneapolis, MN: *Pediatric Ophthalmology & Strabismus* • Albert T. Vitale, MD, Salt Lake City, UT: *Ocular Inflammation & Tumors*

Focal Points Staff

Susan R. Keller, Acquisitions Editor • Kimberly A. Torgerson, Publications Editor

Clinical Education Secretaries and Staff

Gregory L. Skuta, MD, Senior Secretary for Clinical Education, Oklahoma City, OK • Louis B. Cantor, MD, Secretary for Ophthalmic Knowledge, Indianapolis, IN • Richard A. Zorab, Vice President, Ophthalmic Knowledge • Hal Straus, Director of Print Publications

Focal Points (ISSN 0891-8260) is published quarterly by the American Academy of Ophthalmology at 655 Beach St., San Francisco, CA 94109-1336. Print or online yearly subscriptions are \$145 for Academy members and \$205 for nonmembers. The print and online yearly subscription package is \$175 for members and \$250 for nonmembers. Periodicals postage paid at San Francisco, CA, and additional mailing offices. POSTMASTER: Send address changes to *Focal Points*, P.O. Box 7424, San Francisco, CA 94120-7424.

The American Academy of Ophthalmology is accredited by the Accreditation Council for Continuing Medical Education to provide continuing medical education for physicians.

The American Academy of Ophthalmology designates this educational activity for a maximum of two AMA PRA Category 1 Credits™. Physicians should only claim credit commensurate with the extent of their participation in the activity.

Reporting your CME online is one benefit of Academy membership. Nonmembers may request a *Focal Points* CME Claim Form by contacting *Focal Points*, 655 Beach St., San Francisco, CA 94109-1336.

The Academy provides this material for educational purposes only. It is not intended to represent the only or best method or procedure in every case, nor to replace a physician's own judgment or give specific advice for case management. Including all indications, contraindications, side effects, and alternative agents for each drug or treatment is beyond the scope of this material. All information and recommendations should be verified, prior to use, with current information included in the manufacturers' package inserts or other independent sources and considered in light of the patient's condition and history. Reference to certain drugs, instruments, and other products in this publication is made for illustrative purposes only and is not intended to constitute an endorsement of such. Some material may include information on applications that are not considered community standard, that reflect indications not included in approved FDA labeling, or that are approved for use only in restricted research settings. The FDA has stated that it is the responsibility of the physician to determine the FDA status of each drug or device he or she wishes to use, and to use them with appropriate patient consent in compliance with applicable law. The Academy specifically disclaims any and all liability for injury or other damages of any kind, from negligence or otherwise, for any and all claims that may arise out of the use of any recommendations or other information contained herein.

The author(s) listed made a major contribution to this module. Substantive editorial revisions may have been made based on reviewer recommendations.

Subscribers requesting replacement copies 6 months and later from the cover date of the issue being requested will be charged the current module replacement rate.

©2007 American Academy of Ophthalmology®. All rights reserved.

Learning Objectives

Upon completion of the module, the reader should be able to:

- Identify suitable candidates for refractive lens exchange
- Perform appropriate, accurate preoperative evaluation
- Compare monofocal, multifocal, and accommodative intraocular lenses
- Summarize proper surgical technique to minimize complications and improve outcomes

Key words: accommodative intraocular lens, axial length biometry, keratometry, multifocal intraocular lens, refractive lens exchange

Introduction

Refractive surgeons have historically offered procedures for patients desiring spectacle and contact lens independence. With the availability of new technology, however, surgeons are now finding a competitive advantage among their increasingly well-educated clientele by offering improved functional vision as well. Measured by techniques such as wavefront aberrometry, contrast sensitivity, night driving simulation, reading speed, and quality-of-life questionnaires, functional vision represents not only the optical, neural, and psychological capability to see to drive at night or walk safely down a poorly illuminated flight of stairs, but also the ability to read a restaurant menu by candle light or navigate a web page without reliance on progressive or trifocal spectacles. Our goal as refractive surgeons has become crisp, clear, and colorful uncorrected vision at all distances, under all conditions of luminance and glare, much like the vision enjoyed by young emmetropes.

In large part because of the immense success and popularity of LASIK, refractive surgeons have focused on the cornea as the optical element of choice for refractive correction. Excimer laser ablations, with wavefront guidance or prolate optimization, can achieve excellent results with great accuracy and permanence. However, while the cornea remains relatively stable, the human lens changes throughout life. All young candidates for corneal refractive surgery must be advised that they will eventually succumb to presbyopia and the need for reading glasses due to changes occurring in the crystalline lens and the

associated ciliary-zonular apparatus. In a more subtle but nevertheless significant change, lenticular spherical aberration dramatically reverses from negative to positive as we age and causes substantial loss of image quality. Therefore, any refractive correction of the cornea will be overwhelmed by aging changes in the lens. Finally, and in ever-increasing numbers, those who have had corneal refractive surgery will require cataract extraction and intraocular lens (IOL) implantation. So far, the accuracy of IOL power calculation for these patients has remained troubling.

Presbyopia, increasing spherical aberration, and the development of cataracts represent persuasive arguments that prompt the refractive surgeon to look beyond the cornea to the lens. Most commonly, however, the reason to consider refractive lens surgery remains the physical and biological limits of LASIK. In younger patients, with intact accommodation, the insertion of a phakic refractive lens offers a compelling alternative. Beyond the age of 45 any refractive surgical modality that does not address presbyopia offers only a partial solution to a patient's problem.

Science and industry are responding to the demographic changes in society with the development of improved technology for biometry, IOL power calculation, and lens extraction, as well as a wide array of innovative pseudophakic IOL designs. The future holds multiple opportunities for lens-focused refractive surgery. Candidates for surgery will be offered a predictable refractive procedure with a low complication rate and a rapid recovery that addresses most refractive errors, including presbyopia. Surgeons will provide these procedures without the intrusion of third-party payers and re-establish an undisrupted physician-patient relationship; and society as a whole will enjoy the decreased taxation burden from the declining expense of medically necessary cataract surgery for the growing ranks of baby boomers who will have opted for refractive lens surgery and ultimately reach the age of government health coverage as pseudophakes. This combination of benefits represents a driving force that will keep refractive lens procedures at the forefront of ophthalmic medical technology.

Patient Selection Criteria

Age

Age represents the primary criterion for patient selection for refractive lens exchange (RLE). Younger individuals with intact accommodation cannot understand the frustration of the bifocal decades; even at the age

of 39, individuals presenting for LASIK do not always grasp the significance of their impending requirement for reading glasses. The eventuality of cataract surgery resides in the far distant future, and the degradation of visual quality due to advancing spherical aberration has not yet made an impact. Despite thorough counseling and informed consent, individuals who do not yet feel the ravages of presbyopia are rarely candidates for RLE.

Presbyopia

The plano presbyope represents a significant challenge for RLE given the state of the art of IOL power calculation. Even the most careful biometry cannot guarantee emmetropia; the 20/15 presbyope must be counseled that a secondary procedure will likely be necessary to achieve the same quality of distance acuity he or she now enjoys. LASIK, limbal relaxing incisions, and piggyback IOLs represent options for correcting residual postoperative refractive error. It obligates the surgeon to describe the likelihood of these enhancement procedures in advance of the primary surgery.

Myopia

The patient's axial length and risk for retinal detachment or other retinal complications should be considered. Although there have been many publications documenting a low rate of complications in highly myopic clear lens extractions, others have warned of significant long-term risks of retinal complications despite prophylactic treatment. With this in mind, other phakic refractive modalities should be considered in extremely high myopes. If RLE is performed in these patients, complete informed consent regarding the long-term risks for retinal complications should be emphasized preoperatively.

Personality and Lifestyle

Optical aberrations, dysphotopsias, and poorly defined states of asthenopia are part and parcel of anterior segment eye surgery in general and of refractive surgery in particular. The likelihood of foreign body sensation, odd light reflections, and unanticipated color perception only touch the surface of the myriad complaints a surgeon may hear in the postoperative period. Obsessive-compulsive personality types fare poorly with refractive surgery of all types. Patients with depression may not find the solace they seek in spectacle independence. Mutual understanding of reasonable expectations represents the ultimate test of acceptable candidacy for RLE. Utilization of accom-

modative or multifocal IOLs in patients who complain excessively, are highly introspective, or obsess over body image and symptoms should be avoided. In addition, conservative use of these lenses is recommended when evaluating patients with occupations that include frequent night driving and occupations that put high demands on vision and near work (eg, artists, architects, and engineers).

Outcomes

Guidelines with respect to the selection of candidates and surgical strategies that enhance outcomes with multifocal IOLs have been developed. Many are anecdotal reports from experienced refractive surgeons. In general, multifocal IOLs are appropriate for patients whose surgery is uncomplicated and whose personality is such that they are highly motivated to be independent of glasses and not likely to fixate on the presence of minor visual aberrations such as halos around lights. Relative contraindications include the presence of ocular pathologies, other than cataracts, that may degrade image formation such as age-related macular degeneration, uncontrolled diabetes or diabetic retinopathy, uncontrolled glaucoma, recurrent inflammatory eye disease, and corneal disease or previous keratorefractive surgery.

Preoperative Evaluation

Biometry

Axial length measurement remains an indispensable technique for IOL power calculation. Partial coherence interferometry has emerged as a popular modality for biometry. Postoperative results achieved with this technology are considered analogous to those achieved with the ultrasound immersion technique. Extremely user-friendly and less dependent on technician expertise than ultrasound methods, noncontact optical biometry is, however, limited by dense media (eg, posterior subcapsular cataract). Optical biometry machines can also provide keratometry measurements, obviating the need for a second instrument.

Immersion ultrasound has long been recognized as an accurate method of axial length measurement, generally considered superior to applanation ultrasound techniques. The absence of corneal depression as a confounding factor in measurement reduces the risk of inter-technician variability in technique. In addition to having a short learning curve, immersion ultrasound has no limitations in terms of media density and measurement

capability. On the other hand, optical biometry may be superior in eyes with posterior staphyloma because of more precise localization of the fovea.

A near-perfect correlation of immersion ultrasound and optical coherence biometry measurement techniques indicates the high level of accuracy of both of these methodologies.

Keratometry and Intraocular Lens Power Calculation

Intraocular lens power calculations for cataract and RLE surgery have become much more precise with the current generation of theoretical formulas and newer biometry devices. However, IOL power calculation remains a challenge in eyes with prior keratorefractive surgery. The difficulty in these cases lies in accurately determining the corneal refractive power.

Calculating Corneal Refractive Power. In a normal cornea, standard keratometry and computed corneal topography are accurate in measuring four sample points to determine the steepest and flattest meridians of the cornea, thus yielding accurate values for the central corneal power. In irregular corneas—such as those having undergone radial keratotomy (RK), laser thermal keratoplasty (LTK), hexagonal keratotomy (HK), penetrating keratoplasty (PKP), photorefractive keratectomy (PRK) or laser in situ keratomileusis (LASIK)—the four sample points are not sufficient to provide an accurate estimate of the center corneal refractive power. Traditionally there have been three methods to calculate the corneal refractive power in these eyes. These include the historical method, the hard contact lens method, and values derived from standard keratometry or corneal topography. The historical method remains limited by its reliance on the availability of refractive data prior to the keratorefractive surgery. On the other hand, the contact lens method is not applicable in patients with significantly reduced visual acuity. The use of simulated or actual keratometry values almost invariably leads to a hyperopic refractive surprise. It has been suggested that using the average central corneal power rather than topography-derived keratometry may offer improved accuracy in IOL power calculation following corneal refractive surgery.

Holladay II Formula. The IOL calculation formula plays a critical role in obtaining improved outcomes. The Holladay II formula is designed to improve determination of the final effective lens position by taking into account disparities in the relative size of

the anterior and posterior segments of the eye. To accomplish this goal, the formula incorporates the corneal white-to-white measurement and the phakic lens thickness, and uses the keratometry (effective refractive power or *EffRP*) values not only to determine corneal power but also to predict effective lens position. We have found that the use of the Holladay II formula has increased the accuracy of our IOL power calculations. Many new formulas with improving accuracy in IOL power determination have been published in recent years and it would be wise to compare the results from multiple sources before choosing the lens implant.

Informed Consent. It is wise to tell patients as part of the informed consent process that IOL calculations following keratorefractive surgery remain a challenge and that refractive surprises do occur. Explain that further surgery may be necessary in the future to enhance uncorrected visual acuity. Defer any secondary procedures until a full 3 months postoperatively and document refractive stability before proceeding.

Surgical Technique

RLE succeeds in creating spectacle independence only if the final postop refraction includes less than 1 diopter (D) of astigmatism. It is, thus, very important that incision construction be appropriate with respect to size and location. A clear corneal incision at the temporal periphery that is 3.5 mm or less in width and 2 mm long is highly recommended. The surgeon must also be able to utilize one of the many modalities for addressing preoperative astigmatism. Although arcuate keratomies at the 7 mm optical zone can be utilized, there is an increasing trend favoring 600 μ m deep limbal relaxing incisions for the reduction or elimination of preexisting astigmatism.

In preparation for phacoemulsification, hydrodelamination and cortical cleaving hydrodissection are important because they facilitate lens disassembly and complete cortical clean-up. Complete and fastidious cortical clean-up will reduce the incidence of posterior capsule opacification whose presence, even in very small amounts, will inordinately degrade the visual acuity with multifocal IOLs and impede the function of accommodative IOLs. It is because of this phenomenon that patients implanted with multifocal lenses may require Nd:YAG laser posterior capsulotomies earlier than patients implanted with monofocal IOLs.

Key elements of the surgical technique when implanting accommodative IOLs include temporal clear corneal phacoemulsification, with construction of a 3.5 mm incision for implantation. A round, centered 4.0-mm capsulorrhexis ensures in-the-bag fixation of the IOL optic. Atropine 1% solution is administered at the conclusion of the case and at the first postoperative visit to insure that the IOL will settle posteriorly in the capsule.

Intraocular Lens Selection

Table 1 compares features of selected intraocular lenses used in RLE for presbyopia.

Monofocal Lenses

Occasionally implantation of bilateral distance-focused monovision IOLs may represent an appropriate choice for RLE. In particular, extremely hyperopic patients who require bilateral piggyback IOL implantation may be satisfied with correction of their refractive error alone. Patients with a history of successful monovision contact lens wear may find RLE with pseudophakic monovision an appealing option. In addition, patients with a high degree of keratometric astigmatism may require implantation of toric IOLs in addition to limbal relaxing incisions to achieve adequate reduction of their refractive cylinder.

Multifocal Lenses

History. Perhaps the greatest catalyst for the popularization of RLE has been the development of multifocal lens technology. From 1997 until 2005 the only multifocal IOL approved by the FDA for general use in the United States was the Array lens (Advanced Medical Optics, AMO, Santa Ana, Calif.) The Array lens is a zonal progressive IOL with five concentric zones on the anterior surface. Zones 1, 3, and 5 are distance-dominant zones while zones 2 and 4 are near dominant. The lens has an aspheric component such that each zone repeats the entire refractive sequence corresponding to distance, intermediate, and near foci. This results in vision over a range of distances. The lens uses 100% of the incoming available light and is weighted for optimum light distribution. With typical pupil sizes, approximately half of the light is distributed for distance, one-third for near vision, and the remainder for intermediate vision. The lens utilizes continuous surface construction and consequently there is no loss of light through diffraction and no degradation of image quality as a result of surface discontinuities.

In 2005 the FDA approved two new multifocal designs, the ReSTOR lens IOL (Alcon, Fort Worth, Texas) and the ReZoom lens IOL (AMO). The ReSTOR lens employs a central apodized diffractive zone surrounded by a purely refractive outer zone. Apodization means a gradual centrifugal decrease in step height of the 12 diffractive circular structures,

Table 1. Features of Intraocular Lenses Used in Correcting Presbyopia

Feature	Lens		
	ReSTOR SN60D3, MN60D3	ReZoom Lens NXGI	Crystalens AT-45
Add power at the spectacle plane	3.2 D	2.5 D	1.0–2.5 D
Spectacle plane			
Pupil size dependence	Apodization: smaller pupil for reading; distance dominant with larger pupil	Zonal refractive: ≥ 3 mm pupil for reading; distance dominant with smaller pupil	No
Visual disturbances reported	Halos	Halos	No
Incision size	3.0 mm	2.8 mm	2.8 mm
Fixation	Bag only for SN; bag or sulcus for MN	Bag or sulcus	Bag only
Posterior capsule opacification	Increased incidence at haptic/optic junction for SN; square edge for MN	Decreased incidence due to OptiEdge	Decreased incidence in new square-edge model

creating a transition of light between the foci and theoretically reducing disturbing optic phenomena like glare and halo.

New Engineering. The logic of placing the diffractive element centrally depends upon the near synkinesis of convergence, accommodation, and miosis. As the pupil constricts, the focal dominance of the lens shifts from almost purely distance to equal parts distance and near. This approach preserves efficiency for mesopic activities when the pupil is larger, such as night driving. The ReZoom IOL represents new engineering based on the Array lens platform, including an acrylic material and a shift of the zonal progression.

Key Differences. Selection of a multifocal IOL for a particular patient rests on several details of IOL design. One of the key optical differences between the ReZoom lens and the ReSTOR lens, apart from the fact that the former is a refractive lens while the latter is a diffractive lens, is the strength of the add power. The ReZoom lens provides 3.5 D of additional power for near while the ReSTOR lens provides 4.0 D. At the spectacle plane these powers translate to approximately 2.5 D for the ReZoom lens and 3.2 D for the ReSTOR lens. Therefore, the optimal near point for reading will be about 16 inches for ReZoom lens and 14 inches for the ReSTOR lens. A patient who frequently uses a computer monitor may find greater benefit with the slightly more distant near focal point, while a patient who reads paperback books may have greater satisfaction with the closer focus.

Another key difference between these multifocal IOLs is their dependence on pupil size. With a pupil of less than 3 mm the ReZoom lens becomes distinctly distant dominant (because the central zone is distance-focused), while with a small pupil the ReSTOR lens splits light evenly between distance and near (40% distance, 40% near, and 20% loss to destructive interference). On the other hand, a larger pupil enhances the near function of the ReZoom lens and the distance function of the ReSTOR lens. For a frequent night driver there may be an advantage in the design of the ReSTOR lens, while someone who needs to read in dim light may find an advantage in the ReZoom lens. Because postoperative pupil size after lens extraction and IOL implantation is somewhat unpredictable based on preoperative pupil size, it is important to know the technique of photomydriasis. The argon or diode laser can be used to enlarge the pupil and provide near function. It is often useful to demonstrate improved near function with a drop of phenylephrine before undertaking this procedure.

Additional points of distinction between the ReZoom lens and the ReSTOR lens concern structural design differences of the optics and haptics. The acrylic ReZoom lens optic is based on the AR40e platform, while the ReSTOR lens is currently available on the SA60, SN60, or MN60 platform. The 360° sharp posterior design of the AR40e inhibits the development of posterior capsular opacification (PCO) by creating a capsular bend. The SA60AT also features a sharp posterior edge, but PCO may develop through lens epithelial cell migration at the haptic-optic junction. The three-piece construction of the AR40e (and ReZoom lens) enables placement of the IOL in the ciliary sulcus if there is intraoperative compromise of capsular support. If the anterior capsule remains intact in this situation, it is recommended to capture the optic posterior to the capsulorrhexis. While the SA60AT or ReSTOR lens should not be placed in the sulcus, it is noted for its stability within the capsular bag. These points of difference may influence IOL selection.

Clinical Results. The efficacy of zonal progressive multifocal technology has been documented in many clinical studies. Early studies of the one-piece Array lens documented a larger percentage of patients who were able to read J2 print after undergoing multifocal lens implantation compared to patients with monofocal implants. Similar results have been documented for the foldable Array lens. Clinical trials comparing multifocal lens implantation to monofocal lens implantation in the same patient also revealed improved intermediate and near vision in the multifocal eye compared to the monofocal eye.

Of patients implanted bilaterally with the single-piece ReSTOR lens in the FDA clinical investigation, 75.7% reported that they “never” wore spectacles, compared with 7.7% of subjects in a monofocal control group. For the ReZoom lens, data from a sponsored European study that conformed to FDA standards and included more than 200 patients demonstrated that 93.0% never or only occasionally wore glasses.

Contrast Sensitivity. Many studies have evaluated both the objective and subjective qualities of contrast sensitivity, stereoacuity, glare disability, and photic phenomena following implantation of multifocal IOLs. Refractive multifocal IOLs, such as the Array lens, have been found to be superior to diffractive multifocal IOLs by demonstrating better contrast sensitivity and less glare disability. However, more recent reports comparing refractive and diffractive IOLs have revealed similar qualities for distance

vision evaluated by modulation transfer functions but superior near vision for the diffractive lens.

Concerning contrast sensitivity testing, the Array lens has been shown to produce a small amount of contrast sensitivity loss equivalent to the loss of one line of visual acuity at the 11% contrast level using Regan contrast sensitivity charts. This loss of contrast sensitivity at low levels of contrast was only present when the Array lens was placed monocularly and was not demonstrated with bilateral placement and binocular testing. Regan testing is perhaps not as sensitive as sine wave grating tests that evaluate a broader range of spatial frequencies. Utilizing sine wave grating testing, reduced contrast sensitivity was found in eyes implanted with the Array lens in the lower spatial frequencies compared to monofocal lenses when a halogen glare source was absent. When a moderate glare source was introduced, no significant difference in contrast sensitivity between the multifocal or monofocal lenses was observed. However, recent reports have demonstrated a reduction in tritan color contrast sensitivity function in refractive multifocal IOLs compared to monofocal lenses under conditions of glare. These differences were significant for distance vision in the lower spatial frequencies and for near in the low and middle spatial frequencies.

Ultimately, contrast sensitivity tests reveal that in order to deliver multiple foci on the retina, there is always some loss of efficiency with multifocal IOLs when compared to monofocal IOLs. However, contrast sensitivity loss, random-dot stereopsis, and aniseikonia can be improved when multifocal IOLs are placed bilaterally compared to unilateral implants.

Photic Phenomena. One of the potential drawbacks of multifocal lens technology has been the potential for an appreciation of glare or halos around point sources of light at night in the early weeks and months following surgery. Most patients will learn to disregard these halos with time, and bilateral implantation appears to improve these subjective symptoms.

Concerns about the visual function of patients at night have been allayed by driving simulation studies required by the FDA for approval of multifocal IOLs in the United States. The results indicated no consistent difference in driving performance and safety between multifocal and monofocal IOL subjects.

Complications Management. When intraoperative complications develop, they must be handled precisely and appropriately. In situations in which the first eye has already had a multifocal lens implanted, complications management must be directed toward finding

any possible means of implanting a multifocal lens in the second eye. Under most circumstances, posterior capsule rupture will still allow for implantation of a multifocal lens as long as there is an intact anterior capsulorrhexis. Under these circumstances, the lens haptics are implanted in the sulcus and the optic is prolapsed posteriorly through the anterior capsulorrhexis. This is facilitated by a capsulorrhexis that is slightly smaller than the diameter of the optic in order to capture the optic in essentially an "in-the-bag" location. The power of the IOL should be reduced by one-half diopter to account for its anterior location.

If patients are unduly bothered by photic phenomena such as halos and glare, these symptoms can be alleviated by brimonidine tartrate ophthalmic solution, 0.2%. This agent has been shown to reduce pupil size under scotopic conditions and can be successfully administered to reduce halo and glare symptoms. Most patients report that halos improve or disappear with the passage of several weeks to months.

Accommodative Intraocular Lenses

History. The advent of an accommodating IOL has the potential to significantly alter the landscape of cataract and refractive lens surgery. The inspiration for an IOL with axial movement began with several observations made during the 1980s. In 1986 Spencer Thornton published evidence of anterior movement of a three-piece loop lens. With the administration of pilocarpine the lens moved 0.5 mm forward when compared to its position under atropine. At about the same time, Jackson Coleman demonstrated increased intravitreal pressure and decreased anterior chamber pressure during electrical stimulation of the ciliary body in primates, suggesting that a pressure differential occurs concomitantly with axial movement of the lens during accommodation. Coleman's observation provided a potential explanation for the occurrence of axial movement of an IOL during accommodative effort. Meanwhile, Stuart Cumming investigated the ability of some patients to read well through plate haptic IOLs with their distance correction in dim light. He showed an average of 0.7 mm of anterior movement of plate haptic IOLs with pilocarpine compared to a cycloplegic agent. Thus he began the development of an IOL designed to maximize axial movement and restore accommodation to the pseudophakic patient.

Over 9 years, working with Jochen Kammann in Dortmund, Germany, Cumming investigated seven IOL designs. While the first six designs all demonstrated evidence of axial movement, they also tended to dislocate anteriorly. The second design, for example,

displayed average accommodative amplitude of 2.06 D at 25 months. Two of 24 lenses implanted subsequently dislocated. This design also demonstrated retention of accommodation after Nd:YAG capsulotomy.

The seventh and current design of this axial movement IOL is the AT-45 Crystalens produced by eyeonics (Aliso Viejo, Calif.). The lens features hinged haptics with a 4.5 mm silicone optic and a 12.5 mm overall diameter. Polyimide loops adhere to the capsule and prevent dislocation.

Preoperative Assessment. One point of clear agreement among users and critics of accommodative lens technology is the need for precise biometry and IOL power calculation. Applanation biometry is not sufficiently accurate and must be abandoned in order to succeed with this technology. Immersion A-scan is used as a confirmatory test if there are variable test results with the IOL Master (0.1 mm in one eye or 0.2 mm between eyes). Autokeratometry from the IOL Master, supplemented by simulated keratometry values from topography measurements, yields good results. Use topography if you are going to correct preexisting corneal astigmatism, or if the keratometry does not agree with the refractive cylinder (irregular astigmatism). In patients who have had previous incisional keratorefractive surgery use the effective refractive power (EffRP) from the Holladay Diagnostic Summary of the EyeSys Corneal Topographer, or consider using advanced corneal topographic imaging such as Orbscan (Bausch & Lomb) or Pentacam (Oculus) to determine the corneal power.

Once you obtain accurate keratometry and axial length, you can use the Holladay II formula to determine the IOL power. The Holladay II formula is the only widely available formula in the United States that allows in-house regression analysis and continual refinement. It takes into account seven variables to determine the effective lens position. Implementing the Holladay II does require technician time to input the outcomes data; however, it is well worth the extra time and the price. In previous refractive surgery patients, the Holladay II, Haigis-L, or other modern regression formula should be used.

Implementing new technology for biometry and IOL power calculation represents an important investment for the surgeon serious about refractive lens surgery. Given the premium price that our patients will be paying for these procedures, we must continually examine the quality of our work and seek improvements that will enhance outcomes.

Before going to the operating room, make sure the patient has reasonable expectations and thoroughly

understands the informed consent for this procedure. You should promise less and deliver more, something refractive surgeons have been preaching for years. A questionnaire distributed to all patients in an FDA study at 1 year revealed that 73% never or only rarely wear glasses, while the rest continue to wear them some of the time (15%), most of the time (6%) or all of the time (5%). (See Figure 1.) Motivated refractive surgery patients will very likely do better than this. If they still need glasses after surgery, it will most likely be a low-powered pair of reading glasses for certain types of near work. Presbyopic hyperopes may be extremely happy even with this worst-case scenario. Presbyopic high myopes may be among the very happiest RLE patients, and demonstrate remarkably good uncorrected distance and near vision. Presbyopic low myopes may end up trading near for distance, and should be approached a bit more cautiously. It's probably a good idea to ask these people about their activities to determine if they live in a distant-dominant or near-dominant world before choosing the appropriate refractive procedure for them.

Results. Contrast sensitivity testing has shown that the AT-45 Crystalens exhibits quality of vision comparable to standard monofocal IOLs. Patients complain less about glare and unwanted optical effects with the Crystalens as compared to standard monofocal IOLs. Although initially the 4.5-mm optic caused some concern about quality of vision, these concerns have been eliminated as we have gained experience using this IOL. Larger optic segments are being developed. Also, in the few patients who have undergone Nd:YAG laser capsulotomy, we have found that the ability to see well at both distance and near has been retained.

Complications Management. Complications can occur with any procedure, and Crystalens implantation

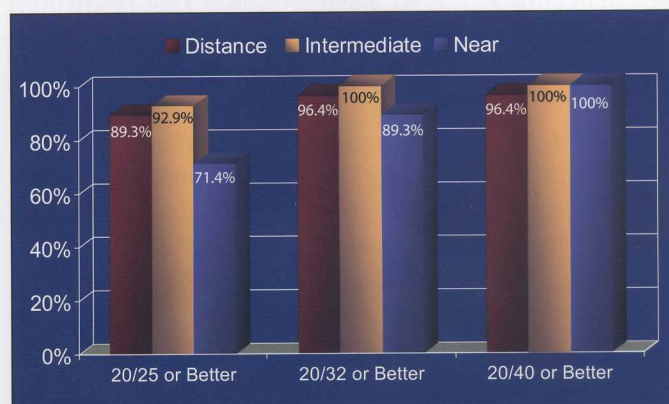

Figure 1. Binocular uncorrected distance and intermediate and near visual acuity with the Crystalens. $n=28$

is no exception. One of the most troubling is anterior subluxation of the lens optic within days of implantation. Typically a patient will have excellent uncorrected acuity on day one and then report a sudden blurring within the next 2 weeks. Examination reveals that the optic has popped forward, producing a myopic shift of about 2 D. These optics must be repositioned because conservative treatment with cycloplegia alone will generally leave residual myopia after initial therapy. The cause of anterior subluxation may be a wound leak through a clear corneal incision, so wound construction is critical. Another possible cause aside from wound leak is that some eyes have a smaller capsular bag which does not permit the haptics to stretch out as the optic moves forward, so that with accommodative effort the lens pops forward. Atropine might help prevent this complication. Finally, it is important to make sure that the lens is placed in the bag right side up, because the hinge grooves are on the front surface of the IOL. This can be checked with a Sinskey hook or a high-magnification side-on view of the lens prior to insertion.

Conclusion

Thanks to the successes of the excimer laser, refractive surgery is increasing in popularity throughout the world. Corneal refractive surgery, however, has its limitations. Patients with severe degrees of myopia and hyperopia are poor candidates for excimer laser surgery, and presbyopes must contend with reading glasses or monovision to address their near visual needs. Phakic IOLs are limited to patients with deep anterior chambers, which make them of limited utility in hyperopes. Additionally, patients in the presbyopic age range or those developing early cataracts may be better served with the one-step process of refractive lens exchange. The rapid recovery and astigmatically neutral incisions

currently being utilized for modern cataract surgery have allowed this procedure to be used with greater predictability for RLEs in patients who are otherwise not suffering from visually significant cataracts.

Successful integration of RLEs into the general ophthalmologist's practice is fairly straightforward since most surgeons are currently performing small-incision cataract surgery for their cataract patients. Although any style of foldable IOL can be used for lens exchanges, multifocal and accommodative intraocular lenses currently offer the best options for addressing both the elimination of refractive errors and presbyopia. Refractive lens exchange with multifocal lens technology is not for every patient considering refractive surgery but does offer substantial benefits especially in high hyperopes, presbyopes, and patients with borderline or soon to be clinically significant cataracts who are requesting refractive surgery.

Mark Packer, MD, FACS, is a practicing ophthalmologist with Drs. Fine, Hoffman and Packer, LLC, Eugene, Oregon. He is also a clinical associate professor, Casey Eye Institute, Department of Ophthalmology, Oregon Health & Science University.

I. Howard Fine, MD, is a practicing ophthalmologist with Drs. Fine, Hoffman and Packer, LLC, Eugene, Oregon. He is also a clinical professor of ophthalmology at the Oregon Health and Science University in Portland, and a co-founder of the Oregon Eye Surgery Center.

Richard S. Hoffman, MD, is a practicing ophthalmologist with Drs. Fine, Hoffman and Packer, LLC, Eugene, Oregon. He is also a clinical associate professor of ophthalmology at the Casey Eye Institute, Oregon Health & Science University.

Clinicians' Corner provides additional viewpoints on the subject covered in this issue of Focal Points. Consultants have been invited by the Editorial Review Board to respond to questions posed by the Academy's Practicing Ophthalmologists Advisory Committee for Education. While the advisory committee reviews the modules, consultants respond without reading the module or one another's responses.—Ed.

1. What are your indications for corneal- vs lens-based refractive surgery?

Dr. Davis: For any pre-presbyopic patient I prefer corneal-based surgery. I find laser vision-correction surgery successful for myopia up to 12 D and for hyperopia up to 4 D. Corneal-based refractive surgery has the benefits of being able to correct a spherical refractive error as well as an astigmatic refractive error.

For presbyopic patients who desire to improve their uncorrected distance vision and their uncorrected near acuity, I will consider lens-based refractive surgery. If they have hyperopic presbyopia or plano presbyopia, particularly if there is any evidence of cataract in this age group, I am much more inclined to perform lens-based surgery rather than corneal-based surgery. However, some of these patients may require subsequent cornea-based laser vision correction to treat residual refractive error or astigmatism.

Dr. Talley-Rostov: I use the following criteria: refraction, patient age, corneal thickness, and presence of any other corneal or lenticular abnormalities. In general, in patients 18 to 60 years of age having between 0 to 8 D of myopia, who have no corneal or lenticular abnormalities, and adequate corneal thickness (defined as residual stromal bed of $>260\ \mu\text{m}$ following LASIK or $>400\ \mu\text{m}$ following PRK), my procedure of choice is wavefront-guided custom LASIK or advanced surface ablation (PRK). In myopes who are 45 to 50 years of age with $>8\ \text{D}$ of myopia or $>5\ \text{D}$ of myopia with thinner corneas (leaving inadequate residual stromal bed), my procedure of choice is a phakic intraocular lens (IOL) with the Verisyse lens. For patients with myopia who are

older than 50 years with inadequate corneal thickness for corneal-based procedures, I consider refractive lens exchange with a new-technology IOL.

For hyperopes younger than 50 years with $<3\ \text{D}$ of hyperopia, my procedures of choice are corneal-based: LASIK for pre-presbyopic patients and conductive keratoplasty (CK) for presbyopes. For patients older than 50 years with <2.5 to $3\ \text{D}$ of hyperopia, CK is my procedure of choice. For hyperopes of any age with $>4\ \text{D}$ of hyperopia, especially those 45 years or older, refractive lens exchange with a new-technology IOL is my procedure of choice.

2. Is it advisable to place a multifocal lens implant as a piggyback lens in a patient who already has a standard monofocal lens implant?

Dr. Davis: If an IOL exchange cannot be performed safely, then I would consider a piggyback multifocal IOL. This lens would need to be a three-piece IOL that could be safely implanted in the ciliary sulcus. An IOL with an anterior square edge should not be used, as this could lead to iris chafing and pigment dispersion with glaucoma. Nevertheless, a sulcus-placed lens may be more prone to decentration given that the ciliary sulcus diameter is greater than that of the capsular bag.

One might consider a multifocal piggyback IOL in a patient who has a monofocal IOL implant in one eye. If cataract or refractive lens exchange is to be performed in the second eye, then the same multifocal lens could be used, or a mix-and-match multifocal or accommodative lens may be preferred to enhance the depth of focus.

Dr. Talley-Rostov: It is inadvisable to place a multifocal lens implant as a piggyback IOL in a patient who already has a standard monofocal lens implant. This is because the combination of optics of a multifocal IOL, combined with the monofocal IOL, can cause further decrease in contrast sensitivity. There are also additional concerns regarding the accuracy of calculation for this combination of piggyback IOLs.

Clinicians' Corner



3. How do you manage a patient who has a multifocal lens implant in one eye but experiences a ruptured posterior capsule during surgery on the fellow eye?

Dr. Davis: If there is sufficient anterior capsular support after an adequate vitrectomy is performed, a three-piece multifocal lens can be placed in the ciliary sulcus. Alternatively, one can use a monofocal IOL in the ciliary sulcus, aiming for slight myopia (-0.50 to -0.75 D). If anterior capsular support is inadequate, then a monofocal IOL should be sutured into the posterior chamber or placed in the anterior chamber, aiming for a similar level of myopia.

Dr. Talley-Rostov: The key to this question is the informed consent process before surgery. Prior to surgery, intraoperative complications, including the possibility of posterior capsular rupture, should be explained and the patient must be made aware that in this event, a multifocal lens implant may not be able to be placed. Centration and IOL calculation are critical to the success of the multifocal IOL implantation. Although IOL optic capture in the bag is possible with the multifocal IOLs, in the event of a small posterior capsular rupture, one must take care to ensure the accuracy of IOL calculation. Decreasing the intended IOL by .5 to 1 D of IOL power is important to prevent unplanned postoperative myopia.

I have had patients who had cataract surgery a number of years ago with a traditional monofocal IOL and subsequently had surgery on their fellow eye with implantation of a multifocal IOL. I have encountered no significant problems in these patients and, with time, patients do well with neuro-adaptation.

4. If patients are unhappy after refractive lens exchange, would you consider exchanging one multifocal implant lens type for another? Would you mix lenses of different design in the same patient?

Dr. Davis: I would consider exchanging one multifocal IOL for another only if I believed this had a good chance of improving the patient's symptoms. For example, if the patient complains of glare and

halos, I am not sure I would simply exchange one multifocal IOL for another, as all multifocal IOLs carry this risk. In such a situation I would encourage the patient to give things time, as these symptoms are very common and tend to get better as neuro-adaptation occurs. If the patient feels that intermediate or near vision is inadequate, I would first check the patient's refractive outcome. If the patient ends up more hyperopic or more myopic than anticipated or has residual astigmatism >0.50 D, this may be the explanation for unhappiness. A laser vision adjustment might be the more appropriate approach to remedy the situation.

I have mixed lenses of different design in the same patient. I have used an accommodative IOL in one eye and a multifocal IOL in the other eye, and I have used two different multifocal IOLs in a single patient. I find that the current accommodative and multifocal IOLs on the market provide excellent distance acuity, but some are better for intermediate vision (Crystalens, ReZoom) and others are better for near vision (ReSTOR). If, after placement of one particular lens in the patient's first eye, the patient complains of a deficit of either intermediate or near vision, I would consider placing a complementary lens in the other eye. I find that neuro-adaptation occurs much more readily when the optical systems in both eyes match as closely as possible.

Dr. Talley-Rostov: It is important to ascertain the exact reasons for their discontent before rushing to exchange the IOL. In general, the ReZoom IOL provides satisfactory intermediate and distance vision. I counsel patients that they will still need to wear a prior of reading glasses for prolonged near vision tasks. The ReSTOR IOL provides satisfactory close and distance vision, but may not provide adequate intermediate vision. I counsel these patients that they may need glasses for computer work or other intermediate activities.

If the patient is unhappy with the results of near vision after multifocal implantation, but is otherwise happy with distance vision, one can take care when operating on the fellow eye to plan for some additional myopia to aid the patient with near tasks. For example, if the patient had a ReZoom lens placed in the first eye, one could consider implantation of a ReSTOR lens in the fellow eye.

Similarly, for patients who have undergone implantation with a ReSTOR IOL in their first eye, but were unhappy with their intermediate vision, one could consider implantation with a ReZoom IOL in their second eye.

It can be helpful to explain to the patient that when the second eye is done, care will be taken to expand his or her range of vision to a more complete range of vision. If the patient is experiencing issues with decreased contrast sensitivity and/or significant night driving issues following multifocal lens implantation, reassure this patient, that with time, neuro-adaptation will occur and the symptoms will likely diminish.

5. Are patients who have had previous LASIK surgery more likely to have better results with one type of IOL or another?

Dr. Davis: Patients with previous LASIK surgery are likely to have the best quality of vision with a monofocal IOL. LASIK reduces contrast sensitivity to a degree and a multifocal IOL could compound that. Additionally, lack of super-position of the optical center of the LASIK ablation zone and the optical center of the multifocal IOL could lead to visual aberrations. This would probably be most apparent if the LASIK ablation was somewhat decentered. However, each case is unique and I would not say that LASIK surgery is an absolute contraindication for placement of a multifocal IOL. Determination of which IOL is best would only come after careful measurements of refraction, topography, and wavefront. Furthermore, patient counseling on potential risks and side effects would be imperative.

Dr. Talley-Rostov: In patients who have had previous LASIK surgery, I have implanted all different types of IOLs, including monofocal, accommodative, and multifocal IOLs. All worked well, with the patients preferring the new-technology IOLs. Such patients should be informed preoperatively that they have an increased chance for an IOL exchange due to some inaccuracies that exist with IOL calculations following LASIK. All IOLs are prone to IOL calculation errors, even when using the latest IOL formulas for IOL surgery following LASIK.

6. What are your concerns about late decentration with multifocal or accommodative lenses? Would you still place a lens in a patient with pseudoexfoliation, loose zonules, or even a decentered capsulorrhexis?

Dr. Davis: Late decentration can occur with any lens type as the capsule contracts. With the accommodative IOL, an uncommon complication called *Z syndrome* can occur. As the capsule contracts, one of the hinges may vault forward on one side, causing the lens to take on a Z shape. This results in tilt of the optic and can lead to induced astigmatism and/or visual aberrations. An Nd:YAG capsulotomy along the haptic can alleviate this in many cases but not all. Late decentration with either a multifocal or an accommodative lens, if significant enough, can induce a loss of best-corrected acuity, glare, and halos, or change in refractive error/astigmatism.

Because there is a greater chance of capsular bag contraction and decentration of the IOL, I would not use one of these lenses in a patient with pseudoexfoliation or loose zonules. If the capsulorrhexis was mildly decentered, I would still consider placing the IOL in the capsular bag. However, if there was significant decentration, I would use either a monofocal IOL or place a three-piece multifocal IOL in the ciliary sulcus.

Dr. Talley-Rostov: In patients with pseudoexfoliation or loose zonules, I routinely implant a capsular tension ring (CTR), since these patients are at risk for IOL decentration no matter which IOL is used. Multifocal IOL placement in a patient with pseudoexfoliation or loose zonules, with simultaneous CTR placement, should not present a problem. The placement of the CTR is the key to success with these patients.

When a decentered capsulorrhexis has occurred, a multifocal IOL can be placed as long as the IOL has enough exposure from the anterior capsule, and as long as the capsulorrhexis is not so large that the IOL cannot be centered in the bag. With accommodative IOLs (Crystalens), I do not recommend placement in patients with pseudoexfoliation or loose zonules (even with a CTR) or with a decentered capsulorrhexis. These IOLs require a pristine bag and perfect placement and centration in the

bag with a capsulorrhexis not less than 5 mm and not more than 6.5 mm. Accommodative IOLs placed under any of these adverse conditions can easily become decentered and need to be removed and exchanged.

7. How do you handle posterior capsular opacities in patients with multifocal intraocular lenses or accommodative lenses?

Dr. Davis: Posterior capsule opacification tends to have a greater affect on patients' vision when they have a multifocal or accommodative IOL. To improve their vision, I am more likely to treat the opacities with an Nd:YAG capsulotomy earlier in these patients. With the Crystalens in particular, I would make certain that the capsulotomy was smaller than the optic. I have seen cases where the Nd:YAG capsulotomy was extended outside of the optic, and the IOL either dislocated posteriorly into the vitreous or vitreous prolapsed anteriorly around the edge of the optic.

Dr. Talley-Rostov: When performing an Nd:YAG posterior capsulotomy in patients with multifocal or accommodative IOLs, care must be taken to create a small central posterior capsulotomy in a circular fashion. It is recommended to avoid performing the posterior capsulotomy with a cruciform pattern, as this may lead to extension of the capsular bag and the potential for IOL dislocation, especially with the Crystalens. One must also take extreme care to avoid pitting the IOL. A "posterior focus setting" can help alleviate this issue.

8. How do you treat over- or undercorrections?

Dr. Davis: For a significant (≤ 2 D) over-/undercorrection, I would do an IOL exchange. For a lesser refractive error, I would perform a laser vision enhancement procedure at 3 months postoperatively. Whether I chose to perform a LASIK procedure or a surface ablation would depend upon the patient's corneal thickness and corneal topography. Because IOL power calculations are not 100% accurate (particularly true in the patient with prior refractive surgery), I think it is important to counsel all patients about the possibility of the need for a

second procedure to fine tune the visual outcome. Furthermore, if a patient will incur any additional charges for a secondary procedure, it is important to discuss this openly up front, prior to the first procedure. If the surgeon does not perform laser vision correction, then it may be of benefit to find a colleague to whom these patients can be referred if necessary. Negotiating a fair price on the patient's behalf should be done.

Dr. Talley-Rostov: If there is a significant (≥ 2 D) over- or undercorrection that is noted immediately postoperatively, and does not improve within 2 to 3 weeks, I perform an IOL exchange. This happens most frequently in patients with a history of previous refractive surgery. For smaller undercorrections, I assess the patient's happiness and further educate the patient regarding the advantages of expanded near vision. If the patient is still unhappy after 3 months of neuro-adaptation, I perform PRK. For smaller (< 2 D overcorrections), I use CK for successful treatment.

9. How much astigmatism will refractive lens exchange patients tolerate, and how do you correct it pre- or postoperatively?

Dr. Davis: Most refractive lens exchange patients do not tolerate more than 0.75 D of astigmatism. The sharpness and quality of the image begins to degrade at this level of cylinder. It can mean the difference between a happy patient and an unhappy one. If the correction of the astigmatism with a phoropter or a trial lens noticeably improves the patient's vision, then an enhancement procedure may be considered. Either a corneal relaxing incision—such as an astigmatic keratotomy or a limbal relaxing incision—or a laser vision-correcting procedure could be performed. I prefer to use laser vision correction because I find it the most precise method. I also find that it allows me to adjust any residual spherical refractive error at the same time. I prefer to wait until 3 months postoperatively to perform this enhancement. Again, whether I perform a surface laser ablation or a LASIK procedure depends upon the patient's corneal thickness, corneal topography, and other findings on examination.

Dr. Talley-Rostov: In general, I have found that refractive lens exchange patients tolerate .75 D or less of astigmatism postoperatively. I do limbal relaxing incisions at the time of RLE. If there is still residual astigmatism postoperatively that is bothering the patient, I either repeat the relaxing incisions or perform CK.

10. Who are the best candidates for refractive lens exchange, and would you operate on eyes with coexisting disease?

Dr. Davis: The best candidates for refractive lens exchange are hyperopic or plano presbyopes who are well educated about the procedure, risks, and outcomes. Such patients are highly motivated to be less dependent on their glasses or contact lenses. They tend to have a personality that is adaptable rather than perfectionist. They understand that their vision after this procedure will not be exactly the same as that which they enjoyed when they were 20 years old. They understand that glare, halos, reduced contrast sensitivity, change in color perception, and fluctuating vision in different lighting conditions are all risks. They understand that some of these symptoms may occur initially but tend to get better with time, particularly once their second eye has had surgery. They also realize that a secondary procedure may be required to achieve their best final outcome. Furthermore, they understand that there are supplemental costs involved with subsequent procedures.

It is best to avoid IOLs for presbyopia in patients with pseudoexfoliation or loose zonules, signs of macular degeneration, significant diabetic retinopathy, other retinal conditions (macular holes, epiretinal membrane), uncontrolled glaucoma, history of recurrent uveitis, presence of corneal dystrophy (Fuchs, keratoconus, pellucid marginal degeneration, extensive anterior basement membrane dystrophy), abnormal pupils (decentered, traumatic), pupils smaller than 3.0 mm, asteroid hyalosis, or strabismus. Additionally, one should be hesitant about placing IOLs for presbyopia in patients with significant dry eyes, corneal scars, or large pterygia; patients with a monofocal in the first eye; and patients with prior radial keratotomies.

Dr. Talley-Rostov: The best candidates for refractive lens exchange are well-informed patients with reasonable expectations, who are older than 50 years, and who are not candidates for a corneal refractive procedure. Other good candidates are hyperopes 35 years or older with ≥ 5 D of hyperopia.

I have operated on patients whose eyes had coexisting disease, as long as the patient had complete informed consent and reasonable expectations. The patient must have adequate understanding of the limitations imposed by the coexisting ophthalmic disease.

11. What is your risk management process for refractive lens patients? Do you use the same consent form as for cataract surgery patients?

Dr. Davis: Our consent form for both types of patients is very similar, as the surgical risks intraoperatively are exactly the same. However, we do spend more time outlining some of the unique risks regarding side effects from the IOLs for presbyopia. I have discussed these side effects above. Most of the consent occurs during the preoperative evaluation with a face-to-face discussion with the surgeon. We also provide pamphlets discussing the different lens types and their advantages and disadvantages.

Dr. Talley-Rostov: For refractive lens exchange patients, I use the same consent form as I do for cataract surgery patients. About 40% to 50% of my cataract patients opt for new-technology IOLs. We have revamped our cataract surgery consent process to include both consent forms and a DVD for informed consent. I use the same consent process with refractive lens exchange patients, since the surgery and risks are the same. Patients are made aware of inherent surgical risks, as well as expectations including scenarios such as posterior capsular rupture with vitreous loss that may negate implantation of a new-technology IOL. We also use informed consent DVDs and informational computer programs to aid in patient education and the informed consent process.

Elizabeth A. Davis, MD, FACS, is a board certified ophthalmologist with subspecialty training in cornea, cataract, glaucoma, and refractive surgery. She is actively involved in speaking, teaching, and research in addition to maintaining a busy surgical practice. She is a partner of Minnesota Eye Consultants, P.A. and is also an assistant clinical professor at the University of Minnesota.

Audrey R. Talley-Rostov, MD, is a managing partner at Northwest Eye Surgeons as a specialist in cornea, external disease, and anterior segment surgery and as a refractive surgeon, Seattle, Washington.

SUGGESTED READING

Colin J, Robinet A. Clear lensectomy and implantation of low-power posterior chamber intraocular lens for the correction of high myopia. *Ophthalmology*. 1994;101:107-112.

Drexler W, Findl O, Menapace R, et al. Partial coherence interferometry: a novel approach to biometry in cataract surgery. *Am J Ophthalmol*. 1998;126:524-534.

Fenzl RE, Gills JP, Cherchio M. Refractive and visual outcome of hyperopic cataract cases operated on before and after implementation of the Holladay II formula. *Ophthalmology*. 1998;105:1759-1764.

Fine IH. Corneal tunnel incision with a temporal approach. In: Fine IH, Fichman RA, Grabow HB, eds. *Clear-Corneal Cataract Surgery & Topical Anesthesia*. Thorofare, NJ: Slack, Inc; 1993:5-26.

Fine IH, Hoffman RS, Packer M. Clear-lens extraction with multifocal lens implantation. *Int Ophthalmol Clin*. 2001;41:113-121.

Fine IH, Packer M, Hoffman RS, eds. *Refractive Lens Surgery*. Heidelberg: Springer-Verlag; 2005.

Haring G, Dick HB, Krummenauer F, Weissmantel U, Kroncke W. Subjective photic phenomena with refractive multifocal and monofocal intraocular lenses. Results of a multicenter questionnaire. *J Cataract Refract Surg*. 2001;27:245-249.

McDonald JE 2nd, El-Moatassem Kotb AM, Decker BB. Effect of brimonidine tartrate ophthalmic solution 0.2% on pupil size in normal eyes under different luminance conditions. *J Cataract Refract Surg*. 2001;27:560-564.

Packer M, Brown LK, Hoffman RS, Fine IH. Intraocular lens power calculation after incisional and thermal keratorefractive surgery. *J Cataract Refract Surg*. 2004;30:1430-1434.

Packer M, Fine IH, Hoffman RS. Functional vision, contrast sensitivity, and optical aberrations. *Int Ophthalmol Clin*. 2003;43:1-3.

Packer M, Fine IH, Hoffman RS. Refractive lens exchange with the array multifocal intraocular lens. *J Cataract Refract Surg*. 2002;28:421-424.

Packer M, Fine IH, Hoffman RS, Coffman PG, Brown LK. Immersion A-scan compared with partial coherence interferometry: outcomes analysis. *J Cataract Refract Surg*. 2002;28:239-342.

Packer M, Hoffman RS, Fine IH. Refractive lens exchange. In: Hardten DR, Lindstrom RL, Davis EA, eds. *Phakic Intraocular Lenses: Principles and Practice*. Thorofare, NJ: Slack Inc; 2004.

Steinert RE, Post CT, Brint SF, et al. A progressive, randomized, double-masked comparison of a zonal-progressive multifocal intraocular lens and a monofocal intraocular lens. *Ophthalmology*. 1992;99:853-861.

Related Academy Materials

Chang DF, ed. *Cataract*. Specialty Clinical Update Online, Volume 1, 2004.

Clear lens extraction (refractive lens exchange). In: *Refractive Surgery*. Basic and Clinical Science Course, Section 13, 2006-2007.

Hill WE, Byrne SF. *Complex Axial Length Measurements and Unusual IOL Power Calculations*. Focal Points: Clinical Modules for Ophthalmologists, Module 9, 2004.

Wallace RB. *Multifocal and Accommodating Lens Implementation*. Focal Points: Clinical Modules for Ophthalmologists, Module 11, 2004.