

# Refractive aspects of cataract surgery

I. Howard Fine, MD, and Richard S. Hoffman, MD

The emphasis in cataract surgery has shifted to perfecting the refractive outcome. More accurate lens power calculations and refinement in techniques to reduce or eliminate surgically induced and preexisting astigmatism have moved us closer to the ultimate surgical result—emmetropia. Multifocal lenses and surgically induced multifocal corneas have the potential to eliminate not only myopia and hyperopia but also the loss of accommodation resulting from the pseudophakic state.

Oregon Eye Associates, 1550 Oak Street, Suite 5, Eugene, Oregon 97401, USA.

**Current Opinion in Ophthalmology** 1996, 7;1:21–25.

## Abbreviation

IOL intraocular lens

© 1996 Rapid Science Publishers  
ISBN 1-85922-816-X ISSN 1040-8738

In his keynote address at the first Ocular Surgery News Symposium on Small Incision Cataract Surgery (New York, NY; 1992), Dr. William Maloney emphasized that we have entered a new millennium. The emphasis in cataract surgery had now shifted from strictly focusing on the extractive aspects of the surgery but the refractive as well. In the intervening years since that symposium much has been learned and new information and techniques have been applied in the quest for the most rapid, most precise uncorrected visual acuity following cataract surgery. With proper measurements including keratometry readings, the use of computerized corneal topography, A-scan measurements, and precise preoperative lens power calculations, we have come a long way in our desire to achieve freedom from postoperative myopia and hyperopia. Small-incision surgery has reduced surgically induced astigmatism and multiple modalities are currently being refined to address preexisting astigmatism and the loss of accommodation that results from the pseudophakic state. It is now possible for substantial numbers of patients to achieve uncorrected visual acuity of 20/40 or better on the first postoperative day, which for a long time had been viewed as an important milestone in cataract surgery.

## Preoperative lens power calculations

Certainly the refractive status of the surgical result is going to depend on the precision of the lens power calculations. Although there is evidence that some formulas for lens power calculations are better for large amounts of preexisting hyperopia [1] and others for large amounts of preexisting myopia, Olsen *et al.* [2] suggested that for the bulk of patients, those with axial lengths between 20 mm to 26 mm, there is more accuracy of lens power calculation with his formula than with the Binkhorst, SRK/T, or the Holiday formulae. He believes the increased accuracy is related to improved anterior chamber depth prediction based on a regression formula that incorporates corneal height, preoperative anterior chamber depth, axial length, and lens thickness.

## Control of surgically induced astigmatism

The move to smaller cataract incisions has been propelled by the desire to reduce or eliminate surgically induced astigmatism and obtain quicker and more stable postoperative visual rehabilitation. Numerous studies have recently been published that investigate the effects of incision size and location on surgically induced astigmatism.



A long-term, 3-year follow-up study by Storr-Paulsen and Henning [3] followed up 32 of their patients after undergoing small-incision phacoemulsification through a 4-mm scleral tunnel incision closed with a single horizontal suture. They reported mean surgically induced astigmatism of 0.63 D at 1 day, 0.01 D at 1 year, and 0.07 D at 3 years postoperatively. These findings validate the long-term stability of small-incision cataract surgery with respect to astigmatic stability and reduced induction of astigmatism.

Feil *et al.* [4] found that following self-sealing small-incision cataract surgery, there was a minimal amount of against-the-rule change from 1 month to 1 year postoperatively. Astigmatism stability had occurred by 1 month leading one to question the need for a single stitch, as used in Storr-Paulsen and Henning's [3] study. Sutures appeared to add little with respect to wound stability or refractive stability.

Levy *et al.* [5] studied the astigmatic changes following cataract surgery using 5.1-mm and 3.5-mm sutureless incisions. They found, as others have previously, that the smaller incision is associated with less surgically induced astigmatism early in the postoperative period, but at 3 months the astigmatism in the two groups was not statistically significantly different. As would be anticipated, the visual acuity was better for the smaller incision group than for the larger incision group in the early postoperative period. After 4 months, however, there was no statistically significant difference between the number of patients from the two groups who had unaided visual acuity of 20/40 or better. Steinert *et al.* [11] have previously documented that at 3 months postoperatively, larger incision cataract patients had similar surgically induced astigmatism to small-incision patients but that there was further against-the-rule decay in the larger incisions that went on for long periods of time while the small-incision patients maintained relative long-term refractive stability [6]. We would expect the same to be true of the patient population in Levy *et al.*'s [5] study.

There is still some question as to the best way to document or measure surgically induced astigmatism during the postoperative period. Hayashi *et al.* [7] measured the correlation between incision size and corneal shape changes in sutureless cataract surgery. They used three different groups undergoing 3.2-mm, 4.0-mm, and 5.0-mm incisions. Because in a number of previous studies keratometric data were frequently inconsistent with the patients' visual acuity, the object of their study was to examine the correlation between incision size, and corneal shape changes using computerized corneal topography in sutureless surgery. Their results demonstrated that although all incision sizes were associated with flattening at the incision site, the 3.2-mm incision

produced no long-term corneal shape changes, whereas both the 4.0- and 5.0-mm incisions caused persistent irregular steepening in the central cornea. These data suggest that the estimation of curvature changes following different incision sizes, shapes, and locations would require the analysis to include corneal topography.

Many surgeons have moved from scleral tunnel incisions to clear corneal incisions because of the advantages of temporal clear corneal surgery, including easier access to the eye, better visualization of intraocular structures, less postoperative inflammation, and the ability to perform the entire procedure without incising vascularized tissue [8]. In a large study involving 60 patients, Kohnen *et al.* [9] compared the induced astigmatism following clear corneal tunnel incisions measuring 3.5 mm, 4.0 mm, and 5.0 mm in length at the temporal location. At 6 months postoperatively the clear corneal 3.5-mm incisions averaged 0.37 D compared with 0.56 D for the 4-mm and 0.70 D for the 5-mm incisions. They demonstrated that the temporal clear corneal tunnel incisions induced clinically minimal astigmatism for 6 months postoperatively depending on incision size.

Nielsen [10] evaluated surgically induced astigmatism from 3.5-mm and 5.2-mm temporal and superior clear corneal incisions and compared them with 3.5-mm and 5.2-mm corneoscleral tunnel incisions at the superior location. He concluded that the corneoscleral incisions of both sizes were astigmatically neutral. Unfortunately, his follow-up was for only 6 weeks and his sample size was small. The 3.5-mm clear corneal incisions induced roughly one-half diopter of with-the-rule or against-the-rule drift, depending on temporal or superior location. Larger amounts of astigmatism were induced with the larger clear corneal incisions. He found that the refractive effect of clear corneal incisions was stable between postoperative day 1 and postoperative week 6, making their astigmatic keratotomy effect more useful and predictable if one wished to consider preoperative cylinder when selecting incision type or location.

The availability of true small-incision surgery is dependent on the availability of foldable lenses. In a long-term study giving data for patients up to 3 years postoperatively, Steinert *et al.* [11] documented the excellent visual acuities and very low complication rate for the first approved foldable silicone lens by the US Food and Drug Administration, the AMO SI-18 (Allergan, Irvine, CA). In another study, Menapace [12] evaluated the most recently introduced silicone intraocular lens (IOL) by AMO, the SI-30. The study followed up patients 6 months postoperatively and demonstrated excellent clinical results and low complication rates. He suggested that increasing the rigidity of the haptics, which were polypropylene, may be advantageous in reducing the already



small rate of IOL decentration. Indeed, we now have available three foldable lenses that have polymethyl methacrylate haptics: the LI-41U (Chiron IntraOptics, Irvine, CA), the SI-40 (AMO, Allergan, Irvine, CA), and the Acrysoft acrylic foldable lens (Alcon, Fort Worth, TX).

### Reduction of preexisting astigmatism

There are essentially three options in the way of addressing preexisting astigmatism. They include combining astigmatic keratotomy along with phacoemulsification and IOL implantation, the use of toric IOLs, and what is currently a rather popular modality—surgery on the steepest axis. Surgery on the steepest axis appears to have been successful in the hands of many surgeons during the early postoperative period, but there are reports from Kammann (Presented at the Twelfth Congress of the European Society of Cataract and Refractive Surgeons, Lisbon, Portugal, 1994) and Lindstrom [13] that state when starting at 1 year postoperatively, there are considerable amounts of against-the-rule drift after oblique axis surgery.

There have been two recent reports on the use of toric IOL implants: one involving loop haptic lenses and the other plate haptic lenses. Shimizu *et al.* [14] implanted toric loop haptic IOLs through a 5.7-mm incision after cataract extraction by phacoemulsification. The lenses had a cylindrical power of either 2 or 3 D that corresponded to a correction of 1.33 and 1.98 D of correction at the spectacle plane. They demonstrated that the maximum allowable lens rotation was 30°, or one clock hour. Beyond this, not only were the beneficial effects of the astigmatic correction eliminated, but negative effects would occur and the preoperative astigmatism would be worsened. Although they did not indicate the incidence of decentration, they believed the maximum acceptable amount of decentration was 1.0 mm. A major disadvantage of this particular lens is that the lens is implanted in an incision that is 5.7 mm.

Feingold [15] reported at the Sixth International South African Congress of Cataract and Refractive Surgery on the initial outcome of the 2 D toric plate haptic lens study. Seventy-eight patients were implanted with this lens, which is similar to the Starr AA-4203 lens, with a modification in axial length from 10.5 mm to 10.8 mm to decrease the possibility of rotation. As in Shimizu's *et al.* [14] study, he indicated that rotation by more than one clock hour would remove the beneficial effects of this lens. The average preoperative keratometric cylinder for this study group was 2.09 D and the average postoperative refractive astigmatism was 1.14 D indicating a reduction in astigmatism by 0.95 D. The difference between the theoretical expected reduction and the actual achieved reduction was 0.06 of a diopter.

Kershner [16] published his keratolenticuloplasty technique which is a combination of arcuate keratotomy and clear corneal surgery as a means of reducing preoperative astigmatism. Surgery is performed through the clear corneal periphery on the steepest axis and, if necessary, an arcuate incision is made 180° away at the 7-mm optical zone. For larger amounts of astigmatism paired arcuate keratotomy incisions are made at the 7-mm optical zone and the incision closest to the temporal periphery is used for the clear corneal cataract incision. Kershner [16] reports uncorrected visual acuity of 20/40 or better in 96% of 1000 patients with at least 24 months of follow-up. He also indicates that there are no complications from the procedure, with the exception of four patients having an astigmatic overcorrection.

Our concern with this technique is that when one is operating through an arcuate keratotomy incision at the 7-mm optical zone, one is only 3.5 mm from the visual axis. We believe access to the cataract is severely limited from this central location and the initial postoperative period would be associated with some edema and distortion of the cornea overlying the visual axis. There is also the concern of axial endothelial cell loss.

### Treatment of pseudophakic loss of accommodation

Many studies in the past have indicated a loss of contrast sensitivity as a result of multifocal lenses. In a very informative article by Winther-Nielson *et al.* [17], patients with diffractive multifocal lenses were studied alongside monofocal patients. Under conditions simulating twilight with central glare, the multifocal patients lost significantly more contrast sensitivity. In addition, adding peripheral glare to daylight conditions also reduced contrast sensitivity by statistically significant amounts. The authors concluded that the diffractive multifocal patients had visual problems associated not only with night driving but also with normal daylight and cloudy weather conditions.

In another study, Boesten *et al.* [18] compared the contrast sensitivity in both eyes of patients who had a monofocal lens in one eye and either a multifocal diffractive lens or a bifocal zonal lens in the other eye. Eyes with the multifocal or bifocal lenses had significant loss of contrast under dim conditions at the lowest contrast levels when compared with monofocal lenses. Under conditions of bright lights, eyes with the diffractive lens had significant loss of contrast acuity compared with the fellow eye containing a monofocal lens, whereas the difference between the bifocal zonal and monofocal eyes was not significant.

Gills [19] discovered that many of his patients who have undergone small-incision cataract surgery in conjunction with corneal relaxing incisions for preexisting astigma-



tism have maintained excellent uncorrected distance and near acuities. He believes that this increased depth of focus or "omnimetropia" is partly due to large power variations across the central cornea (Fig. 1). Interestingly, these multifocal corneas were not found to reduce contrast sensitivities when compared with control subjects, as had been the case with multifocal IOLs. This raises a new possibility of correcting, at the time of cataract surgery, not only preexisting hyperopia, myopia, and astigmatism, but also the resulting loss of accommodation that is characterized by the pseudophakic state.

### Postoperative alterations in refractive spherical equivalent

For a long time it has been clinically evident that three-piece foldable lenses with prolene haptics experience some myopic shift, and plate haptic foldable silicone lenses experience some hyperopic shift during the postoperative period. This is almost certainly due to fibrosis and contracture of the capsular bag. In the case of plate haptic lenses, as the bag fibroses, the lens is bowed posteriorly inducing some hyperopia. This is in contradistinction to the prolene haptic three-piece lenses that start out as anteriorly located loop haptic lenses but as the bag fibroses and contracts, the haptics become located more in the plane of the optic and there is a net anterior movement of the optic resulting in some myopic shift.

There is a report by Shammas [20] of postoperative hyperopic shifts which he believed was the result of fibrosis and contracture of the capsule and which he reversed by placing relaxing incisions in the capsulorhexis with a Nd:YAG laser. This presents an interesting possibility with respect to alterations in the postoperative status of patients, one that may become increasingly important as foldable lenses that utilize PMMA haptics with lasting memory come into greater use. Even late in the postoperative period one could expect the PMMA to exert its long-term memory in reestablishing its previous configuration if the forces of capsular contraction were relieved.

### Conclusions

One of the most important service ophthalmologists perform is restoring vision to patients limited by decreasing vision as a result of cataract. Moving in the direction of a major emphasis on the refractive components of cataract surgery has truly performed miracles for our patients. Improvement in technology and technique has dramatically reduced the visual deficit and limitation of activities previously present in the postoperative period. We look forward to new challenges in cataract surgery and to new therapeutic options provided by expanding technology.

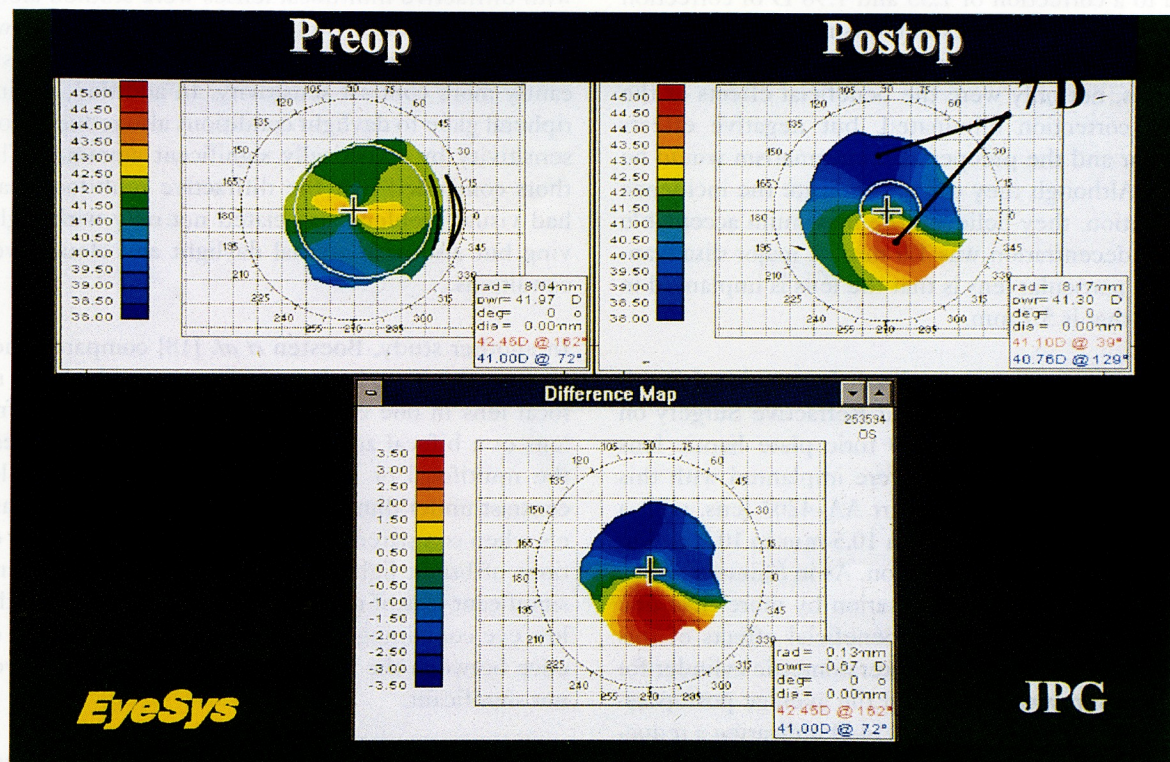


Fig. 1. Seven diopter power variation in a cornea undergoing clear corneal cataract extraction with adjacent corneal relaxing incision. This patient has 20/30 and J1 unaided visual acuity. (Courtesy of J.P. Gills, MD.)



