

New techniques and instruments for lens implantation

I. Howard Fine, MD, James S. Lewis, MD, and Richard S. Hoffman, MD

Although no major breakthroughs have recently emerged in the area of lens insertion techniques and technology, small incremental advancements continue to take place for the placement of foldable intraocular lenses through small incisions. Folders have become more innovative in their ability to effectively fold lenses, and inserters have been downsized and enhanced to allow insertion through smaller incisions with more effective purchase of the lens. New cartridge injectors are increasing in popularity because of their ease of use and ability to pass through smaller incisions, especially with modifications. In addition, increased knowledge regarding techniques and complications of noncapsular supported intraocular lenses continues to be gained, adding to our ability to choose the proper technique for secondary lens insertion in these selected patients.

Oregon Eye Associates, 1550 Oak Street, Suite 5, Eugene, OR 97401, USA.

Current Opinion in Ophthalmology 1998, 9;1:20-25

Abbreviations

AC	anterior chamber
IOL	intraocular lens
PC	posterior chamber
PMMA	polymethyl methacrylate

© 1998 Rapid Science Publishers
ISSN 1040-8738

Although no major changes with respect to techniques and devices have been forthcoming since this subject was last reviewed in *Current Opinion in Ophthalmology* in 1995 [1], small improvements in techniques and instrumentation for the placement of intraocular lenses (IOLs) continue to occur. As the trend toward phacoemulsification with the use of foldable IOLs grows [2], familiarity with these devices will take on increasing importance. In addition, our knowledge regarding the safety, efficacy, instrumentation, technique, and complications of nontraditionally supported posterior chamber IOLs continues to advance.

Folding and insertion forceps for three-piece foldable intraocular lenses

There has been a definite trend toward the development of separate instruments for folding and inserting IOLs rather than using the insertion device to fold the IOL. A greater amount of energy is required to fold an IOL than to hold it in its folded position. As a result, instruments that hold the folded IOL for implantation in the eye can be made somewhat smaller and finer than would be necessary if they were also utilized for folding the IOL.

The Fine Universal III forceps (Rhein #05-2339-R, Rhein Medical, Tampa, FL) is a modification of the Fine Universal II forceps. It has been downsized with ultrathin blades and allows a smaller profile to be placed through the incision because of the hollowing out of the blades that hold the folded lens in place (Fig. 1). The forceps is calibrated for loading with most loading forceps and devices. The direct-acting angled jaws release the lens slowly, and the device is useful for all three-piece foldable lenses, including acrylics.

The Nichamin loader (Rhein #05-2342) and insertion forceps (Rhein #05-2344) represent interesting modifications of previous instruments because of the double tabs on the folding instrument, which prevent the lens from tilting during the loading process (Fig. 2). The insertion forceps has taller and thinner blades, which maximize the surface area around the folded optic, preventing a folded lens from flipping out of its jaws during loading and insertion. It is also useful for all three-piece foldable silicone and acrylic lenses.

Rhein Medical has upgraded the Nichamin devices with the development of the Nichamin II loader and inserter (#05-2346 and #05-2348) (Fig. 3). The special canopy blades of the loader are compatible with a 5.5-mm and

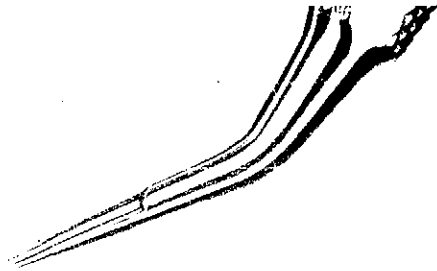



Fig. 1. The Fine Universal III forceps (Rhein #05-2339-R; Rhein Medical, Tampa, FL). (Courtesy of Rhein Medical.)

6.0-mm foldable lens and prevent the optic from migrating out of the jaws. The special window in the blades ensures a precise grasp of the folded optic with the inserter, and the distal tips have tying platforms for tucking the leading haptic into the fold of an optic. The thin blades of the inserter allow for insertion through a smaller incision and are designed for 5.5-mm foldable lenses in all dioptric ranges, as well as a 6.0-mm lens of up to 22 D.



A



B

Fig. 2. A, The Nichamin loader (Rhein #05-2342). B, The Nichamin inserter (Rhein #05-2344). (Courtesy of Rhein Medical.)

The Buratto insertion forceps (Asico AE-4275; American Surgical Instrument Corp., Westmont, IL) was designed specifically for the acrylic lens. It has extremely delicate contoured blades, which allow for positive purchase of the lens and insertion through a 3.5-mm incision with a 6-mm AcrySof optic (Ciba Vision Corp., Atlanta, GA).

Rhein's Lehner II loader and inserter (=05-2376 and =05-2377) is specifically designed for both 5.5-mm and 6.0-mm acrylic foldable lenses (Fig. 4). The lens is placed on the center beam of the loader, and the inserter is placed on the outer anterior surface of the lens. The blades of the inserter are pushed down to fold the lens as it is purchased for insertion. The crescentric blades of the inserter grasp the lens around the periphery, protecting the central optic from damage or impressions and allowing the insertion of the lens through a smaller incision than would be possible if the lens were purchased closer to the fold.

Technique for three-piece foldable intraocular lenses using folders and forceps

All three-piece foldable lenses are being manufactured with polymethyl methacrylate (PMMA) haptics to increase haptic stability and decrease the rate of lens decentration. Older lens insertion techniques for use with Pro-lene (Ethicon Inc., Somerville, NJ) haptics utilized tucking the haptics between the folded halves of the lens prior to insertion through the incision. This technique does not work well with PMMA haptics, which may snap permanently or kink when being tucked. In general, the technique for folding and implanting three-piece lenses with PMMA haptics is as follows.

The lens is purchased with the insertion forceps held in the dominant hand and then placed into the folder or on the surface, from which it can be purchased by the folder in the nondominant hand. The lens is folded, and then the insertion device, in the dominant hand, holds the

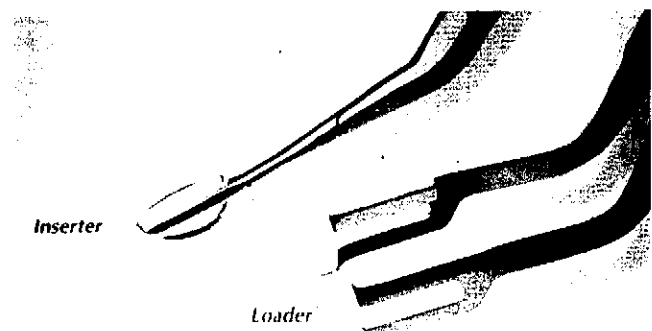


Fig. 3. The Nichamin II inserter (Rhein #05-2348) and loader (Rhein #05-2346). (Courtesy of Rhein Medical.)




Fig. 4. The Lehner II inserter (Rhein #05-2377) and loader (Rhein #05-2376). (Courtesy of Rhein Medical.)

folded lens, which is ready for insertion. When lenses are folded across the 12- and 6-o'clock axis, they are oriented in the holding or insertion instrument with a leading and trailing haptic. In contrast, folding across the 10- and 4-o'clock axis (oblique axis) or across the 9- and 3-o'clock axis will yield a folded configuration with both haptics pointed inferiorly with the fold superiorly. After insertion through the incision, the hand is then brought into a proper position so that the fold is superior. After the leading haptic has been delivered under the distal capsulorhexis, the forceps are slowly opened (direct-acting forceps) or closed (reverse-acting forceps), allowing the lens to unfold. The trailing haptic is then usually dialed into the capsular bag to the left. Using the folded orientation with both haptics directed inferiorly negates the need for dialing in the trailing haptic because both haptics will unfold into the capsular bag, pulling the optic through the capsulorhexis.

The Alcon AcrySof lens, which requires 3.5- to 4.0-mm incisions for 6.0-mm optics and 3.2- to 3.5-mm incisions for 5.5-mm optics, is now packaged in a wagon wheel dispenser. The easiest folding instrument to use for these lenses is the Rhein folder, because the tips have been extended to make it easier to remove the lens from its wagon wheel packaging. The forceps can be turned with the tips down in the nondominant hand. The tips go into the slots on both sides of the optic, allowing purchase of the lens so that it can be picked up and placed on a drop of viscoelastic. The forceps are then turned so that the tabs are down. The lens is grasped and folded, and then the insertion device in the dominant hand is used to purchase the lens.

Some surgeons prefer to fold this lens along the 9- and 3-o'clock axis with the haptics downward so that the posteriorly staked haptic (the tip of which enters the incision first) can be pulled up and placed between the folded lens and the blade of the forceps and inserted in such a way that the hand is supinated with the fold to the right. Oth-

ers prefer folding along the 10- to 4-o'clock oblique axis so that for modified-C loops there is a cross-swords appearance of the haptics [3,4]. This particular folded lens can be delivered into the eye by placing the leading haptic (posteriorly staked haptic) through the incision compressed against the folded optic during insertion through the wound. The anteriorly staked haptic (the tip of which is the last portion to enter the eye), by virtue of its orientation with an oblique folded lens, also becomes compressed against the optic during insertion. Still others recommend folding acrylic lenses along the 6- to 12-o'clock axis because of a perceived benefit of allowing for less traumatic insertion through a smaller incision size [5].

Although it is not mandatory, some have found that warming acrylic lenses prior to insertion allows for easier folding and manipulation. Lenses can be warmed to body temperature by placing the lens package in the pocket of a circulating nurse. If other warming methods are used, the lenses should not be warmed beyond 100°F and should be warmed for no more than 10 minutes at this temperature because of potential lens fogging [5].

Cartridge injector systems

Some of the newest advances in lens insertion technology surround the use of cartridge injector systems. There are many perceived advantages of implanting foldable IOLs with injector systems, as compared with folding forceps. These advantages include the possibility of greater sterility, ease of folding and insertion, and implantation through smaller incisions.

Greater sterility with injector systems is believed to occur because the IOL is brought directly from its sterile package to its sterile cartridge and inserted into the capsular bag without ever touching the external surface of the eye, as is the case for lenses in folding forceps. Although this advantage would suggest a lower rate of endophthalmitis with injector systems, recent clinical studies have shown no significantly different rate of bacterial contamination of the anterior chamber after implantation of silicone lenses with a forceps versus an injector [6].

Perhaps the most appealing advantage of injector systems is that the lens can be loaded by a nurse or technician without the use of an operating microscope, further streamlining the procedure. In addition, inserting foldable lenses with a cartridge device is generally felt to be easier than insertion with forceps, and these lenses can usually be implanted through a smaller incision when delivered by means of an injector, compared with an insertion forceps [7,8].

AMO has designed a new cartridge injector system called the Unfolder AMO Phacoflex II Implantation System (Allergan Medical Optics, Irvine, CA) for second-genera-

tion silicone three-piece foldable lenses with PMMA haptics (Fig. 5). It has a cartridge with a 45-degree bevel-down configuration that can implant the SI40 (AMO; Allergan Medical Optics, Irvine, CA) foldable silicone IOL with PMMA haptics through a 2.8- to 3.0-mm clear corneal incision. The tip of the insertion rod has a Teflon cap so that tearing of the lens is avoided. After the viscoelastic-lined cartridge has been loaded and the lens folded, the cartridge tip is inserted through the incision into the anterior chamber with the bevel down. The bevel is then rotated slightly to the surgeon's left so that the leading haptic is pointing to the surgeon's left as the optic is advanced with the handpiece rod. The leading loop of the IOL should always point to the surgeon's left throughout the entire procedure. As the optic is advanced, the bevel will need to be rotated down and then to the surgeon's right to keep the lens in proper orientation (Fig. 6). The leading haptic is placed into the bag as the IOL is released. Once the optic is completely out of the cartridge, the handpiece rod is retracted proximal to the end of the trailing haptic and then advanced with the bevel down to place the trailing haptic within the bag. Placing the bevel completely within the capsulorhexis at this stage of insertion keeps the optic in place and ensures placement of the trailing loop.

AMO has developed an injection system for its foldable acrylic IOL, the Clariflex lens. The Clariflex has a 6.0-mm optic with PMMA haptics and can be implanted through a 3.5-mm incision via a cartridge injector. Alcon's 5.5-mm AcrySof (MA30BA) can be injected with a standard cartridge through a 3.0-mm incision, and some have reported injecting this lens through a 2.8-mm incision [9].

As more emphasis has been placed on inserting lenses through smaller incisions, concerns have arisen regarding alterations in wound architecture produced by forc-




Fig. 5. AMO Unfolder cartridge injector system (Allergan Medical Optics, Irvine, CA). (Courtesy of Allergan Medical Optics.)

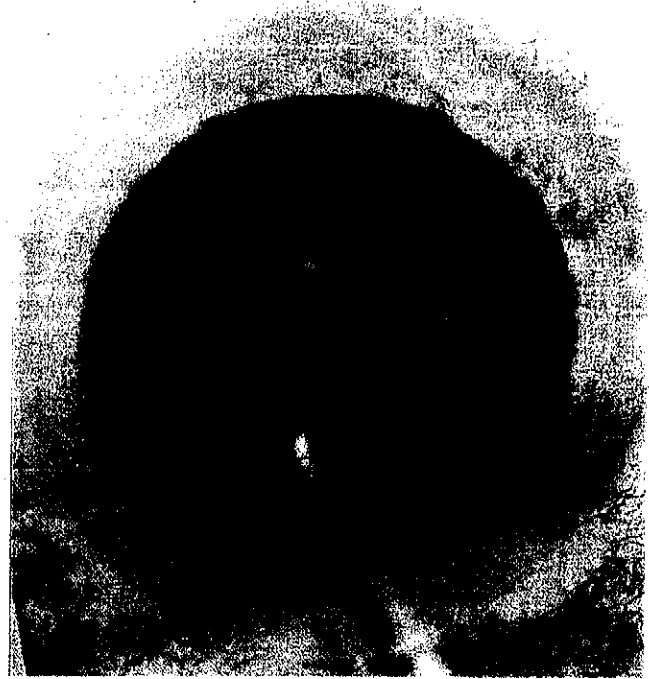

Fig. 6. Implantation of a three-piece foldable intraocular lens using the AMO Unfolder cartridge injector. The cartridge bevel is rotated to the right to keep the lens in the proper orientation as it is ejected by the soft blue Teflon tip. (Courtesy of Allergan Medical Optics.)

ing folders and inserters through incisions too small for nontraumatic insertion. Kohnen *et al.* [10^{*}] found that foldable IOLs could be inserted through the smallest incisions when an injector was used. However, these incisions enlarged approximately 11% from tearing of corneal tissue. Corneal incision tearing was found to be more pronounced with injector insertion than with forceps insertion, and final incision size after lens insertion was found to be similar for each type of lens inserted, despite the initially smaller size for injector-inserted lenses.

The concern with regard to traumatic lens insertion stems from the possibility that self-sealability will be compromised by the stretching of corneal incisions with a possible increased risk of wound leaks and endophthalmitis. It is because of this that some are urging a balance between producing the smallest incision for lens insertion and allowing a large enough incision for atraumatic lens insertion. Gills [11] has found that injection of the Staar AA 4203 plate haptic IOL (Staar Surgical, Monrovia, CA) can be accomplished atraumatically through a 2.5-mm clear corneal incision by cutting a V-shaped notch 1-mm wide in the inferior aspect of the oval bevel of the Staar I-ATFC-45 injector (Staar Surgical).

Sutured posterior chamber intraocular lenses

During the past 2 years, the era of the intracapsular cataract extraction has slipped even further into the past. This leaves us with fewer uncomplicated aphakes seeking secondary IOL insertion. Consequently, our ability to determine the ideal noncapsular IOL placement procedure is confounded by numerous variables. These include the many intraoperative complications concurrent with the loss of adequate capsular support—namely; vitreous presentation and incarceration, corneal endothelial compromise, iris and angle damage, persistent nuclear and cortical material, glaucoma, macular edema, retinal detachment, and uveitis. The identity of the optimal procedure remains elusive because prospective controlled studies may never be realized.

Nevertheless, surgeons strive to improve techniques and evaluate the various procedures for lens insertion for those without adequate support. Although endoscopy [12] and mirror-guided needles [13] aspire to enhance the precision of suture placement, they are neither commonly available nor necessarily safe and effective. Some have published [14] and even more have tried the use of foldable IOLs for sulcus suture fixation to minimize wound size and surgical inconvenience. Unfortunately, these implants lack rigidity and haptics bearing islets—characteristics probably necessary for modern suture fixation [15].

Menezo *et al.* [16] and others have added a third player to the competition between Kelman-style open-loop anterior chamber (AC) IOLs and large optic all-PMMA posterior chamber (PC) IOLs in these cases of severely compromised capsules. They have suggested a nonangle-supported Worst-Claw anterior chamber lens, hoping to avoid angle damage and exacerbation of glaucoma by the unique geometry of this implant. They have proven this choice a viable alternative in select cases.

Holland *et al.* [17] performed gonioscopic analysis of scleral suture-fixated haptics and recognized the development of a fibrotic membrane around haptics when they were located within the sulcus but found no such stabilizing construct when the haptics extended beyond the sulcus. This may explain why McDermott and Puklin [18] encountered cicatrization to the pars plana of a sutured PC IOL that required haptic amputation and excision before retinal reattachment could be achieved.

The German literature [19] showed quantitatively comparable blood aqueous barrier integrity in patients with both traditional PC IOL insertion and scleral fixation when measured 3 months following surgery. This corroborates the clinical success of PC IOL suturing in cases of moderately compromised corneal endothelial function.

Despite the growing number of surgeons utilizing modern islet-bearing haptic implants, controlled and measured ab externo techniques, and methodical knot burial, a number of reputable anterior and posterior segment surgeons cling to and espouse blind suture passes (ab interno), ineffectual scleral flaps, grooves, and even blatant knot externalization. In addition to donor corneas and sclera, processed pericardium has been particularly helpful in cases of late suture exposure and in those instances in which the sutures stubbornly refuse to bury. Some highly skilled surgeons routinely perform double transcleral sulcus fixation under topical anesthesia (Crandall A, University of Utah, personal communication, July 1997).

One of the most fascinating recent articles by Teichmann and Teichmann [20] demonstrated 16 potential suture paths through single-islet-containing haptics (actually, they showed over 64 possibilities). Although several were benign, many induced torque and lens tilt, while others made knot burial impossible. This may help to explain why some surgeons and series have an unusually high degree of suture exposure and lens tilt. The proponents of some new IOLs with two islets per haptic originally designed to provide so-called four-point fixation, may yield even more convoluted suture paths, exposed knots, and lens tilt instead of greater stability. It may be possible to support one haptic by a capsular remnant and the other through sulcus suture fixation. However, poor lens position and chronic uveitis (Lewis JS, Wills Eye Hospital, Philadelphia, unpublished data, November 1996) are common with this one-point fixation technique and should be discouraged.

One series from the University of Pittsburgh [21] describes the use of sulcus suture fixation in eight aphakic contact lens-intolerant children. Clearly, sulcus suture fixation can now be considered mainstream. The surgeon faced with inadequate capsular support can choose between a variety of AC IOLs, iris suture fixation, and scleral suture fixation. The decision is best based on the surgeon's familiarity with the technique and clinical judgment.

Conclusions

Small incremental advancements continue to take place for the placement of foldable IOLs through small incisions. Folders have become more innovative in their ability to effectively fold lenses, and inserters have been enhanced to allow insertion through smaller incisions with more effective lens purchase. New cartridge injectors are increasing in popularity because of their ease of use and ability to pass through smaller incisions. In addition, increased knowledge regarding techniques and complications of noncapsular supported IOLs continues to be gained, adding to our ability to choose the proper technique for secondary lens insertion in these selected patients.

Acknowledgments

We would like to acknowledge Rhein Medical for assistance in acquiring photographs of their various folders and inserters and Allergan for allowing us to print photographs of their Unfolder AMO PhacoFlex II Implantation System. Special thanks to Dick Castle's Oregon Medigraphics for his graphics expertise.

References and recommended reading

Papers of particular interest, published within the annual period of review, have been highlighted as:

- Of special interest
- Of outstanding interest

1. Fine IH, Lewis JS: **New techniques and instruments for lens implantation.** *Curr Opin Ophthalmol* 1995, **6**:46–52.
 2. Leaming DV: **Practice styles and preferences of ASCRS members—1996 survey.** *J Cataract Refract Surg* 1997, **23**:527–535.
 3. Fine IH: **Response.** *J Cataract Refract Surg* 1992, **18**:207–208.
 4. Oh KT, Oh KT: **Optimal folding axis for acrylic intraocular lenses.** *J Cataract Refract Surg* 1996, **22**:667–670.
- Demonstrates the various folding patterns for acrylic IOLs in addition to suggesting the optimal folding orientation.
5. Shugar JK: **Implantation of AcrySof acrylic intraocular lenses.** *J Cataract Refract Surg* 1996, **22**:1355–1359.
 6. Weindler J, Spang S, Jung WK, Ruprecht KW: **Bacterial anterior chamber contamination with foldable silicone lens implantation using a forceps and an injector.** *J Cataract Refract Surg* 1996, **22**:1263–1266.
 7. Steinert RF, Deacon J: **Enlargement of incision width during phacoemulsification and folded intraocular lens surgery.** *Ophthalmology* 1996, **103**:220–225.
 8. Mackool RJ, Russell RS: **Effect of foldable intraocular lens insertion on incision width.** *J Cataract Refract Surg* 1996, **22**:571–574.

9. Miller KM, Grusha YO, Ching ECP: **Injecting the Alcon MA30BA lens through a Staar 1-MTC-45 cartridge [Letter].** *J Cataract Refract Surg* 1996, **22**:1132.
 10. Kohnen T, Lambert RJ, Koch DD: **Incision sizes for foldable intraocular lenses.** *Ophthalmology* 1997, **104**:1277–1286.
- Determines the minimal incision sizes required for implantation of a variety of different foldable IOLs and evaluates the effect of incision size on tissue damage.
11. Gills JP: **Cutting notch from insertor lessens incision trauma [letter].** *J Cataract Refract Surg* 1997, **23**:11.
 12. Jurgens I, Lillo J, Buil JA, Castilla M: **Endoscopic-assisted transscleral suture fixation of intraocular lenses.** *J Cataract Refract Surg* 1996, **22**:879–881.
 13. Tsai JC, Rowsey JJ, Fouraker BD, Stevens SX, Young DA, Polack PJ: **Use of a mirror needle holder with transsclerally sutured posterior chamber intraocular lenses.** *Ophthalmic Surg Lasers* 1996, **27**:720–724.
 14. Regillo CD, Tidwell J: **A small-incision technique for suturing a posterior chamber intraocular lens.** *Ophthalmic Surg Lasers* 1996, **27**:473–475.
 15. Lewis JS: **Sulcus fixation without flaps.** *Ophthalmology* 1993, **100**:1346–1350.
 16. Menezo JL, Martinez MC, Cisneros AL: **Iris-fixated Worst Claw versus sulcus-fixated posterior chamber lenses in the absence of capsular support.** *J Cataract Refract Surg* 1996, **22**:1476–1484.
 17. Holland EJ, Djalilian AR, Pederson J: **Gonioscopic evaluation of haptic position in transsclerally sutured posterior chamber lenses.** *Am J Ophthalmol* 1997, **123**:411–413.
 18. McDermott PL, Puklin JE: **Pars plana cicatrization of sewn-in posterior chamber intraocular lens haptics.** *Ophthalmic Surg Lasers* 1997, **28**:239–240.
 19. Willwerth AE, Kremer T, Kermeking H, Schmitz P, Gerke E: **Disruption of the blood-aqueous barrier after implantation of scler-fixed posterior chamber lenses. Early postoperative phase and long-term outcome.** *Ophthalmologie* 1997, **94**:24–29.
 20. Teichmann KD, Teichmann IA: **The torque and tilt gamble.** *J Cataract Refract Surg* 1997, **23**:413–418.
 21. Biglan AW, Cheng KP, Davis JS, Gerontis CC: **Results following secondary intraocular lens implantation in children.** *Trans Am Ophthalmol Soc* 1996, **94**:353–379.