

# Cortical cleaving hydrodissection technique includes cortical cleanup

*Hydrodissection beneath the capsule allows removal of the cortex en masse, eliminating that portion of the procedure in which posterior capsular ruptures occur.*

by **I. Howard Fine, MD**  
Special to *OCULAR SURGERY NEWS*

Most people consider hydrodissection to be a technique that separates the nucleus from the cortex. Frequently, when hydrodissection is not in the cortical layer itself but is somewhat deeper in the nucleus, what is achieved is actually hydrodelineation, in which an epinuclear shell is separated from a more compact central nuclear mass.

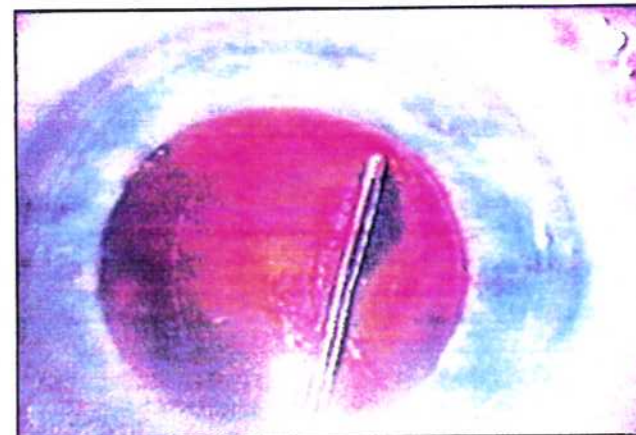
In a similar manner, I have found that if I can get very close to the anterior capsule at the initiation of hydrodissection, I can put a fluid wave just under the anterior capsule in such a way that it separates the cortex, or most of the cortex, from the capsule. When this happens, as it does most of the time now in my hands, the lens can be divided into an epinuclear zone with most of the cortex attached, and subsequently hydrodelineation, as a result of a more compact central nuclear mass. The technique utilizes a

capsulorhexis that tends to be small, with an average 4- to 4.5-mm size being optimum. This results in a large anterior capsular flap and enables greater ease in accomplishing this type of hydrodissection. The anterior capsular flap is elevated with a 26-ga blunt cannula prior to hydrodissection and then fluid is allowed to dissect, carefully, just under the anterior capsule near the equator of the lens.

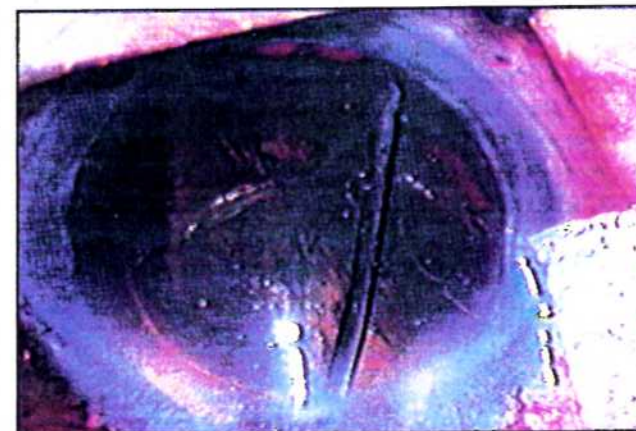
In most cases, one can see a small disk of fluid, which spreads in the plane under the anterior capsule and starts to separate cortex. Gentle continuous pressure will result in a fluid wave that passes circumferentially in the zone just under the capsule, cleaving the cortex from the capsule in most locations. When the fluid wave has passed around the posterior aspect of the lens, the entire lens will bulge forward due to the fluid behind the lens within the capsular bag.

At this point, I depress the central portion of the lens with the side of the

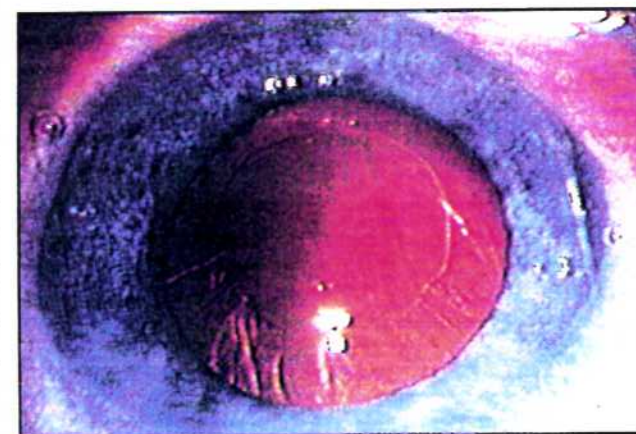
**1**  
*Tenting of anterior capsular leaf prior to hydrodissection.*

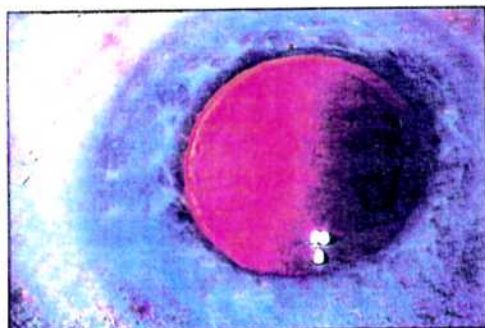


**2**  
*Fluid wave passing posteriorly behind the nucleus and cortex.*

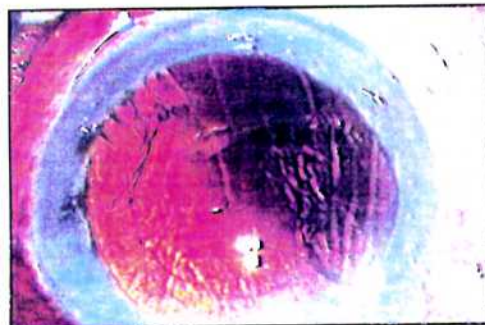


**3**  
*Few cortical wisps remain inferiorly and at 1 to 2 o'clock following removal of the epinucleus. The clarity of the anterior capsular leaf documents cleavage of the cortex from the capsule.*

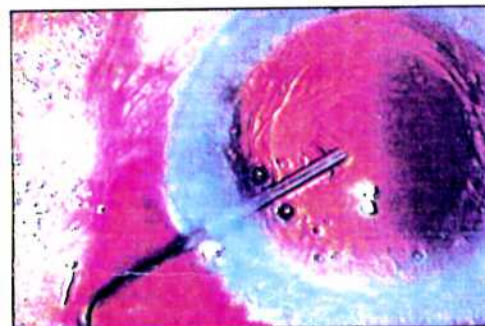




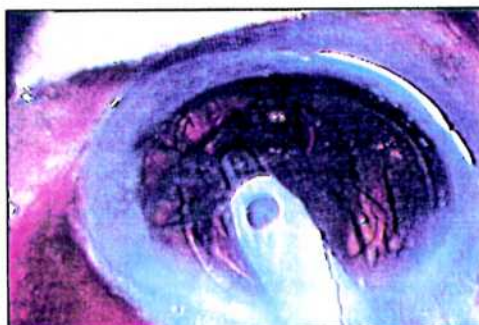**4**  
Clean capsular bag following removal of the epinucleus with the exception of a few cortical strands at 1 to 2 o'clock.



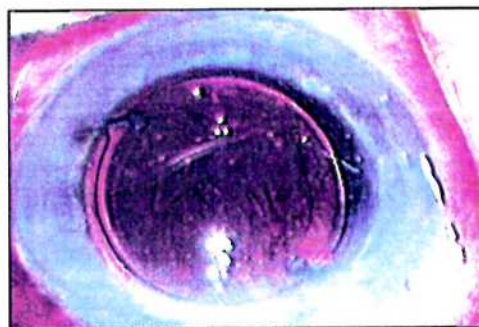
**5**  
Large amount of retained cortex following removal of the epinuclear shell.



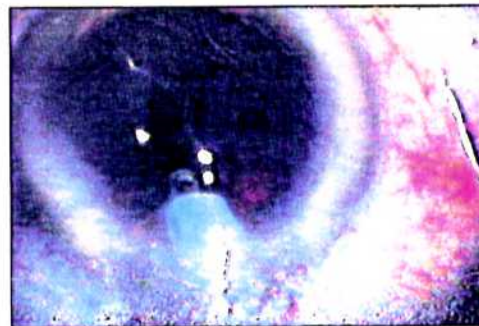
**6**  
Viscoelastic filling the capsular bag and draping the cortex over the anterior capsule after polishing the posterior capsule.



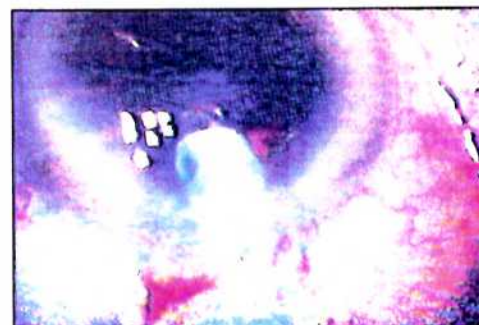**7**  
Easy mobilization and removal of cortex in the presence of a posterior chamber IOL accompanying residual viscoelastic removal.



**8**  
Clean capsular bag following removal of cortex along with residual viscoelastic in the presence of the posterior chamber IOL.



**9**  
Mobilization of residual cortex as an intact shell with both superior quadrants simultaneously stripping from the capsular fornix.



**10**  
Entire upper half of the cortical shell being removed as a result of hydrodissecting cleavage of cortical/capsular connections.

cannula in such a way as to allow fluid to come from behind the lens under the anterior capsular flap and exit from the capsular bag. This gives a cleaner cleavage of cortex from capsule anteriorly and totally mobilizes the lens in such a way that the lens can spin freely within the capsular bag. I often repeat the hydrodissection starting in the opposite inferior quadrant.

I then proceed with hydrodelinea-tion. After removing the hard central portion of the nucleus by chip-and-flip or cracking, I mobilize the resulting epinuclear shell with a flipping maneuver and remove it. In approximately 80% to 85% of the cases, the result is a very clean capsular bag, with the exception of a few loosely adherent scattered strands of cortex. After the IOL has been inserted, these strands can be removed along with residual viscoelastic using the I/A tip, leaving a clean capsular bag.

If there is a lot of cortex remaining, I polish the posterior capsule in the area exposed by the capsulorhexis using a 27-ga Terry squeegee. The capsular bag is then filled with viscoelastic at the center of the bag posteriorly. The viscoelastic spreads laterally elevating the anterior capsular flap and, because of its viscosity, drags remaining cortex so that it is draped over the anterior capsular flap as the viscoelastic extrudes out

of the capsulorhexis. The IOL is then implanted through the capsulorhexis, leaving residual cortex anterior to the IOL. The removal of residual viscoelastic is accompanied by the mobilization and aspiration of residual cortex without difficulty, anterior to the IOL, leaving a clean capsular bag.

In this technique, irrigation and aspiration of cortex as a separate step can be omitted, thereby eliminating that portion of the procedure in which posterior capsule disruption most frequently occurs. Cortical cleanup is accomplished in the presence of a posterior chamber IOL, which protects the posterior capsule by holding it remote from the aspiration port.

However, if one wishes to complete cortical cleanup prior to lens implantation, the residual cortex can

almost always be mobilized as a separate and discreet shell (reminiscent of the epinucleus) without ever turning the aspiration port down to face the posterior capsule. Alternatively, the phaco handpiece can be left high in the anterior chamber while the second handpiece strokes the cortex filled capsular fornices. This frequently results in the cortical shell floating up, as a single piece, and its exit through the phaco tip in I/A mode. This occurs because careful hydrodissection has cleaved most of the cortical capsular adhesions. ■

**Author information:** I. Howard Fine, MD, is in private solo practice, specializing in cataract/IOL and anterior segment; is clinical professor of ophthalmology at Oregon Health Sciences University; with offices at 1550 Oak St. Suite 5, Eugene, OR 97401.