

CLEAR CORNEAL CATARACT INCISIONS

I. Howard Fine, MD

In their atlas, *Ocular Surgery Under the Microscope*, Harms and Mackensen¹⁵ devoted a chapter to the use of a von Graefe incision in clear cornea for intracapsular cataract extraction. Kelman¹⁶ himself believed that the best way to remove a cataract using phacoemulsification was through a corneal incision. Troutman¹⁹ was also an advocate of corneal approaches to cataract extraction and was perhaps the earliest and most enthusiastic American proponent of attempts to reduce surgically induced astigmatism at the time of cataract surgery. More recently, Arnott¹ in England, Galand¹³ in Belgium (using his envelope technique of extracapsular cataract extraction), and Robert Stegmann in South Africa (personal communication, 1992) have all proposed clear corneal incisions for cataract extraction. The leading proponent in the modern era of clear cornea phacoemulsification has been Shimizu²² from Japan.

Over the last decade, a number of major advances have occurred in cataract surgery. Routine use of peripheral iridectomy has been eliminated. Improved wound integrity has resulted in the elimination of most of the restriction on postoperative patients' activities. In most cases, cortical cleaving hydrodissection eliminates the need for cortical cleanup as a separate step after phacoemulsification.⁹

Since 1990, major improvements have occurred as a result of the introduction and de-

velopment of small-incision cataract surgery using foldable intraocular lenses (IOLs) inserted through self-sealing scleral tunnel incisions.^{7,20} Small-incision sutureless surgery has dramatically reduced surgically induced astigmatism and complications such as wound slippage, cyclodialysis, and hyphema.

Scleral tunnel incisions are still associated with some problems, however. The procedure requires conjunctival incisions, with their attendant bleeding and usually the need for cautery. A tight scleral tunnel can cause oarlock problems with the phacoemulsifier handpiece, distorting the cornea and thus compromising the view of the intraocular structures. In addition, there is still some incidence of hyphema from scleral vessels. As a result of these persistent problems, a number of surgeons have turned to clear corneal incisions for phacoemulsification and implantation of foldable IOLs.

EARLY CLEAR CORNEAL INCISIONS

To avoid the unpredictability of superiorly located scleral wounds at the time of secondary anterior chamber IOL implantation, I began inserting secondary anterior chamber implants through the temporal edge of the clear cornea more than 15 years ago. These incisions were closed with three interrupted 10-0 nylon sutures that remained in place for approximately 3 months. Within a short time after

Adapted from Fine IH: Clear corneal incisions. International Ophthalmology Clinics 34:59-72, 1994; with permission.

From the Department of Ophthalmology, Oregon Health Sciences University, Portland, Oregon

OPHTHALMOLOGY CLINICS OF NORTH AMERICA

VOLUME 8 • NUMBER 3 • SEPTEMBER 1995

547

suture removal, these incisions were noted to be very stable with respect to astigmatism and differed from superiorly placed incisions in that they did not drift against the rule (ATR) over time. At that time, I believed these incisions were more stable with respect to ATR drift because the effect of gravity was parallel to the incision rather than perpendicular to it as in superiorly located incisions.

Cravy³ subsequently conducted a prospective study comparing temporally placed incisions to superiorly placed incisions and documented the dramatic increase in stability of the temporally placed incisions. He contended that eyelid blink was the major culprit in ATR drift for superiorly placed incisions. It is likely that both gravity and eyelid blink tend to create a drag on the incision, which causes ATR drift when it is located superiorly. With temporally placed incisions, these forces are better neutralized because the incision is parallel to the vector of the forces.

In 1986, when I began using foldable implants as an investigator for several IOL manufacturers, I also began to use clear corneal incisions for patients with functioning filtering blebs. Phacoemulsification was performed through 3-mm incisions central to the conjunctival insertion in clear cornea, usually to one side of the bleb. The incisions were widened to 4 mm for implantation of a foldable lens and closed with two radial sutures (Fig. 1). Because of the small size of the incisions, the patients were rapidly visually rehabilitated.

In early 1992, I modified the procedure by making longer corneal tunnels for phacoemulsification and folded IOL implantation and

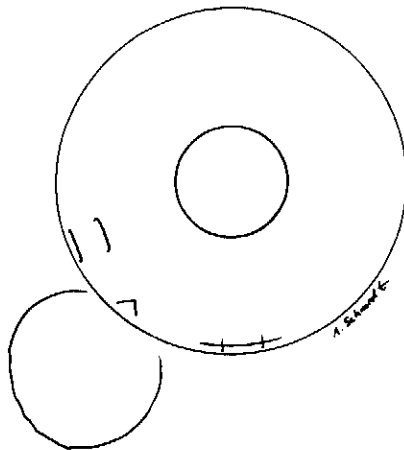


Figure 1. Radially sutured corneal incision for phacoemulsification and intraocular lens implantation in presence of preexisting filtering bleb.

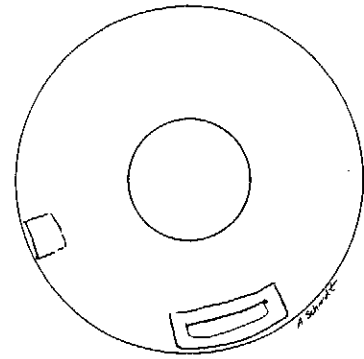


Figure 2. Single-stitch corneal tunnel incision for phacoemulsification and intraocular lens implantation.

closed these with a single 10-0 nylon corneal suture parallel to a tangent to the limbus (Fig. 2), modeled after Shepherd's single stitch.²¹ These patients experienced very little surgically induced astigmatism and very rapid visual rehabilitation.

Subsequently, I developed a systematic approach for self-sealing corneal tunnel incisions located at the temporal periphery. In April 1992, I presented my initial experience in San Diego at the American Society of Cataract and Refractive Surgery Symposium² and then in Sao Paulo at an international symposium sponsored by the Brazilian Society of Cataract, Intraocular Implant and Refractive Surgery.¹⁰ At that time, my incision was modeled after a paracentesis or side-port incision, which was a single-plane, beveled, clear corneal, astigmatically neutral, and self-sealing incision. I believed that, with some alteration in available instrumentation and folding technology, we would be able to use a similar incision for phacoemulsification and IOL implantation.

Initially, I used a diamond knife to create a straight beveled incision with identical construction to a paracentesis. The tunnel had a straight-line entry through epithelium as well as into the anterior chamber through Descemet's membrane (Figs. 3 and 4). This architecture was essential for the self-sealing characteristics of the wound.⁴ One advantage of this procedure was avoidance of conjunctival and scleral incisions, with their attendant bleeding and need for cautery. In addition, shortening the tunnel, relative to the standard scleral tunnel incision, led to greater maneuverability of the phacoemulsifier handpiece and lens inserters through the tunnel.

The temporal location of the incision appeared to provide several advantages. The distance between the temporal corneal periphery




Figure 3. Construction of single-plane, beveled corneal tunnel incision.

and the visual axis is the longest in the cornea, and therefore flattening around the incision is less likely to create flattening at the visual axis. My early experience with clear corneal incisions in this location during secondary IOL implantation had shown them to be refractively stable. Working at the temporal periphery, there is no need to turn the eye down as when working over the brow, and therefore the bridle sutures are not necessary. With the iris plane parallel to the light of the microscope, the red reflex is enhanced and there is marked improvement in visualization of intraocular structures. In addition, this particular location allows greater access to the incision than when working over the brow. Finally, at this location, the lateral canthal angle is directly beneath the incision, the irrigation fluid drains naturally, and therefore one is rarely working "under water" as when working over the brow.

The corneal tunnel incision is beneficial not only for patients with functioning filtering blebs but also for cataract candidates who might need glaucoma filtering surgery in the future. The procedure does not compromise future filtration options. It is particularly beneficial for patients on anticoagulant medications and those with bleeding diatheses, as the operation occurs entirely through avascular structures. Patients with dry-eye syndromes, scleritis, and ocular pemphigoid benefit from this incision site as opposed to incising conjunctiva and tunneling through limbal or scleral sites.

The corneal tunnel incision lends itself extremely well to topical anesthesia, which is another advancement in cataract surgery.^{5, 24} Finally, there is a considerable decrease in surgical and staff time and less instrumentation and therefore a lowering of surgical costs.

I later altered the incision architecture by making a perpendicular groove in the cornea at the incision's external edge to thicken the external edge of tunnel roof, as suggested by Williamson.²³ Currently, I have abandoned the perpendicular groove in favor of a straight beveled incision 2-mm long and 2.6- to 3-mm wide.

CURRENT METHODS OF CLEAR CORNEAL INCISION

Technique

The technique for temporal clear corneal incision requires that the surgeon be on the side or at the superior corner of the operating table, with the assistant positioned at the head of the bed. A Fine-Thornton fixation ring (Mastel Instruments, Rapid City, SD) (Fig. 5), with the opening to the surgeon's left, atraumatically stabilizes the eye. A 1-mm-wide paracentesis is made at the left (Fig. 6). Aqueous humor is replaced by injecting a viscoelastic substance into the anterior chamber angle distal to the paracentesis without overfilling the eye. This creates a stable eye that distorts minimally and




Figure 4. Self-sealing corneal tunnel incision

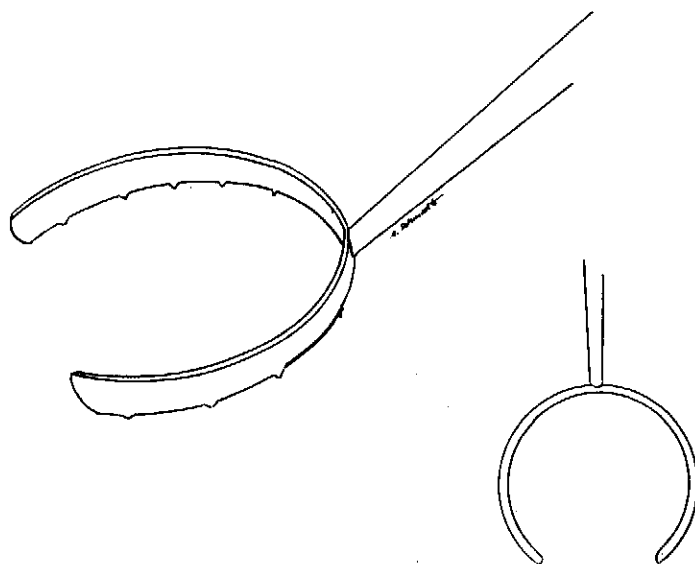


Figure 5. Fine-Thornton fixation ring.

allows for reproducible entry with a diamond knife.

The Fine-Thornton ring is held with the surgeon's other hand, and the globe is again fixed, this time creating access to the temporal periphery of the clear cornea. The diamond blade is flattened against the globe with the tip at the anterior edge of the corneal vascular arcade, thus allowing for a planar incision through the cornea. The blade I currently use is produced by Huco Company of Hauterive, Switzerland, and is depicted in Figure 7. Beveled up and down on all edges, this blade is 4-mm long, 3-mm wide, and 0.17-mm thick. The distance between the 90° tip and the line joining the 45° shoulders is 2 mm. The angled mount and blade can be retracted into the handle for protection between uses. The blade is

advanced into the cornea in the plane of the cornea. When the shoulders of the blade reach the line of the external incision, the tip is turned down so as to cut Descemet's membrane and enter the anterior chamber (Fig. 8). Once the anterior chamber is entered by the tip, the knife is restraightened and advanced in a planar course to the blade mount (Fig. 9), which reproducibly results in a 3 × 2-mm corneal tunnel (see Fig. 4). (For phacoemulsification machines with handpieces that are usable through a 2.6-mm incision, I use a Diamatrix trapezoid knife [Diamatrix, The Woodlands, Texas] which creates an incision 2.6-mm wide internally and 2.9-mm wide externally.)

My standard endolenticular phacoemulsification procedure, crack and flip phacoemulsification, is then performed (see also article by

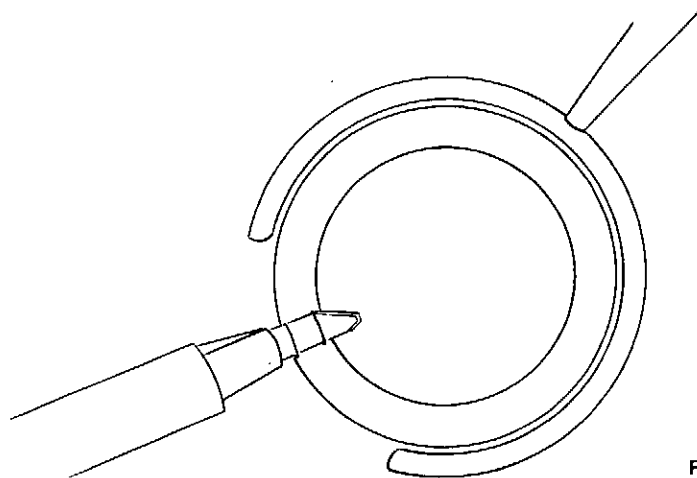


Figure 6. Construction of the side-port incision.




Figure 7. Huco diamond knife.

Dillman and associates "Crack and Flip Phacoemulsification" elsewhere in this issue).¹² The phacoemulsifier handpiece is slipped into the incision bevel down without elevating the roof of the tunnel. After phacoemulsification is complete, the capsule is expanded with a viscoelastic substance. The trapezoid incision (2.6-mm wide internally) does not have to be widened for implantation of the Staar AA4203 plate haptic silicone lens if the new microinjector with the 45° bevel-down cartridge (Staar Surgical, Monrovia, CA) is used. The beveled cartridge allows for easier entry into the slitlike corneal tunnel incision without exerting traction on the roof of the tunnel with a forceps. Back-and-forth rotation and downward pressure as one advances the cartridge into the eye allow the bevel tip to insinuate itself into the incision with minimum distortion of the incision (Fig. 10). The screw mechanism of the Staar injector is engaged, which allows for delivery of the lens into the eye and implantation directly into the capsular bag (Fig. 11). The bevel creates a wider opening by which the lens can leave the cartridge and allows for implantation with less lens rebound energy and less potential trauma to the intraocular structures.

A new folding system and downsized insertion forceps (Fine Folding forceps and Univer-

sal II Insertion forceps, Rhein Medical, Tampa, Florida) have been developed for implanting AMO's second generation three-piece foldable silicone lenses (SI30) through these clear corneal incisions enlarged to 3.25 to 3.50 mm (Fig. 12).⁸ {Note: The author has no financial interest in this instrumentation}. With presently available first generation three-piece foldable silicone (i.e. AMO SI26, IOLAB, LU40I) lenses, enlargement of the tunnel with a keratome to 3.25 mm to 4.0 mm is necessary. AMO has developed a new injector and cartridge that has the potential to implant their 1st generation three-piece foldable silicone lenses through clear corneal incisions 3.0 mm wide.¹¹

Finally, the viscoelastic fluid is removed and the anterior chamber is reconstituted through the side port. A 26-gauge cannula on a 2-mL syringe is used to inject buffered saline solution forcefully into both sides of the tunnel (Fig. 13). This causes temporary stromal swelling and forces the roof of the incision into contact with the floor of the incision in almost all cases. I believe that the major mechanism of self-sealability is, as in sutureless automated lamellar keratoplasty (ALK), endothelial pumping of water and sodium out of the cornea (Color Plate 5, Figs. 1-3). This creates a downward force on the dome of the cornea keeping the roof of the incision stuck to the

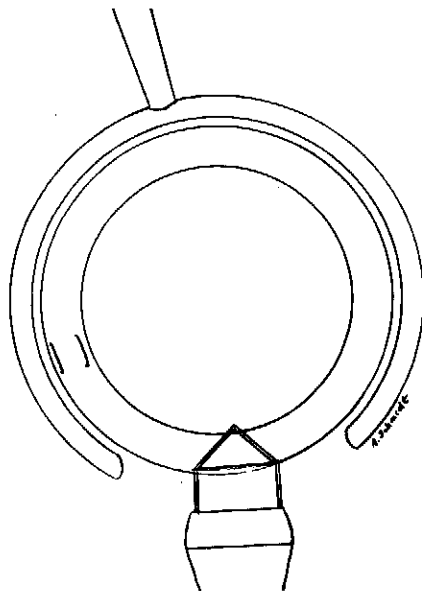


Figure 8. Shoulder of diamond knife at the external incision, indicating that the tip is 2mm into clear cornea.

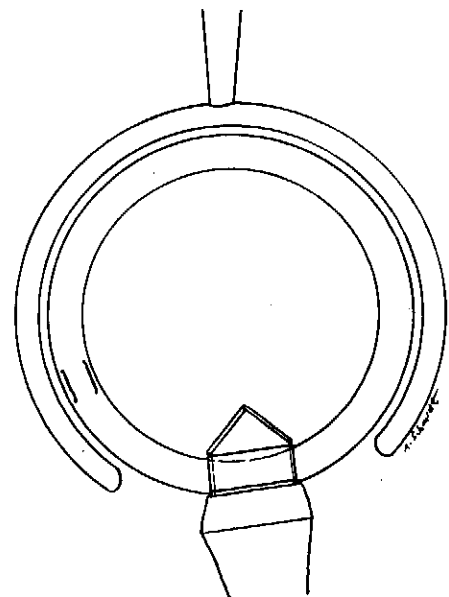


Figure 9. Diamond blade advanced to the mount.

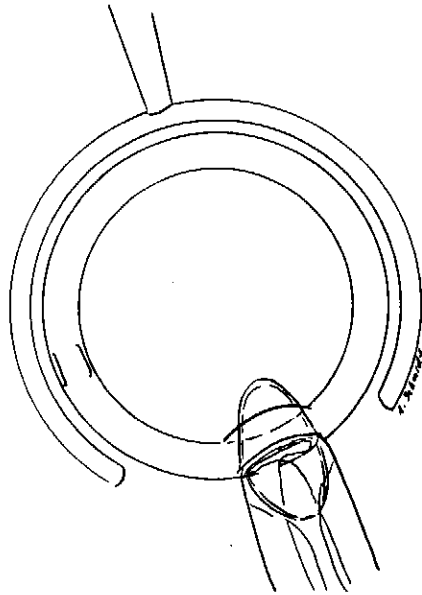


Figure 10. Advancing the beveled cartridge into the incision without instrumenting the roof of the tunnel.

floor of the incision. The incision is tested by staining the incision with fluorescein dye and depressing the posterior lip of the incision forcefully with the surgeon's index finger or knuckle (Color Plate 5, Figs. 4 and 5). If the adequacy of the seal is in doubt, a single 10-0 nylon radial suture is placed.

Postoperatively, eyes operated on in this way appear remarkably uninfamed and, when combined with topical anesthesia, have immediate eyelid blink, motility, and vision, thus eliminating the need for an eye patch.

RESULTS AND COMPLICATIONS

Among a consecutive group of 136 3-mm wide clear corneal cataract surgery eyes with no pathology other than cataract, 71% achieved an uncorrected visual acuity of 20/40 or better on the first postoperative day. Astigmatically, data from a consecutive series of 280 patients with 3-mm-wide incisions were analyzed. The patients experienced an average of 0.5 diopters increase in keratometric cylinder on postoperative day 1, which diminished to a mean level of 0.25 D by the 1- to 2-week examination. Using vector methods of computing surgically induced astigmatism, I found a mean induced cylinder of approximately 1.0 D at 1 week, which regressed to 0.7 D at 2 to 3 months.

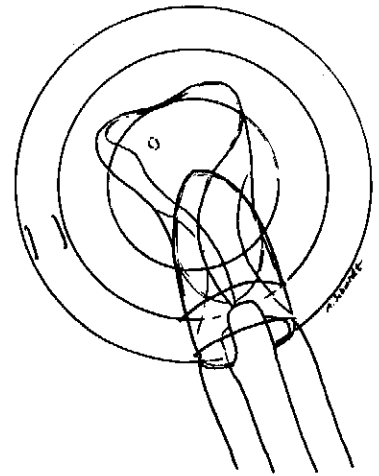


Figure 11. Leading edge of plate haptic lens unfolding inside the capsular bag

Our data on postoperative astigmatism fell within the range reported for sutureless 3.2 to 4.0 mm scleral tunnel incisions reported by Ernest, Grabow, and Martin.²⁰ With temporal corneal incisions, however, our induced astigmatism, although slight, was "with the rule." This was advantageous for the large majority of cataract age patients whose preoperative astigmatism was "against the rule."

In the first 2000 patients in whom I used this technique, there have been very few complications.⁸ One of the first patients in whom the incision was made with a metal keratome at 12 o'clock suffered an infectious endophthalmitis and a poor visual result. One patient with a preexisting compromised endothelium suffered mild corneal decompensation but

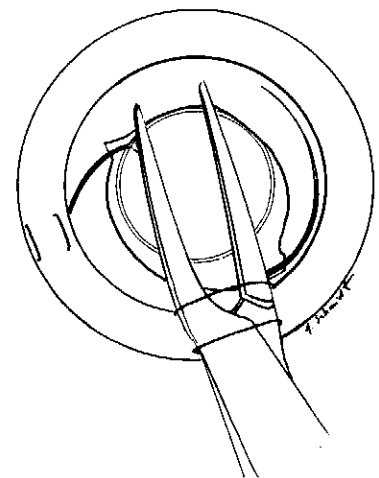


Figure 12. Implantation of three-piece foldable intraocular lens through corneal tunnel incision.

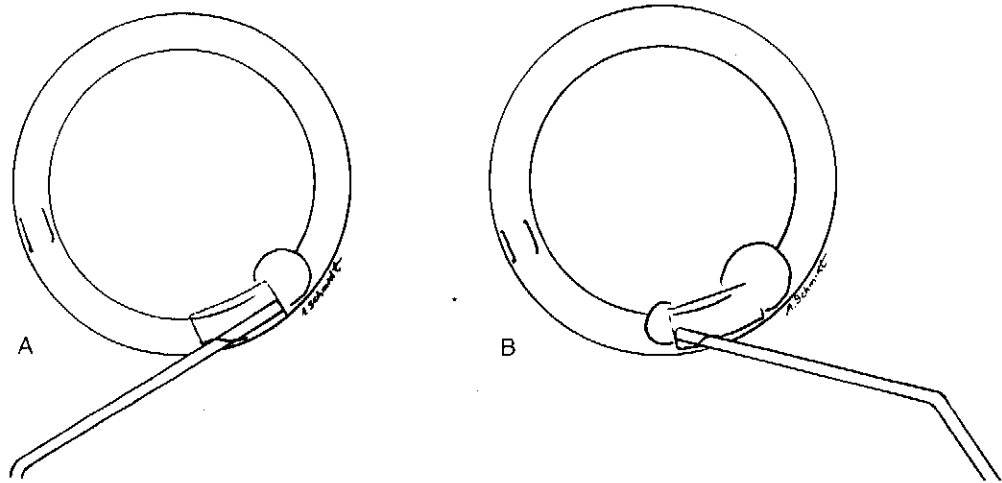


Figure 13. A, B, Enhancing the seal of the incision by hydrating the corneal stroma at the sides of the tunnel.

achieved a postoperative visual acuity of 20/40. Fewer than 2% of the patients required suture closure at the time of surgery. In two early cases, a very shallow to flat anterior chamber was observed on the first postoperative day. One of those patients responded to the placement of a disposable soft contact lens with full reformation of the anterior chamber. The other was returned to the operating room on the second postoperative day for placement of a single radial suture. Both of these patients achieved 20/20 corrected visual acuity. I have had a zero incidence of postoperative shallow anterior chamber in the past 2.5 years.

Other surgeons have reported similar results. Grabow¹⁴ reports slightly increased endothelial cell loss with corneal incisions, especially in compromised endothelium and superiorly located incisions. James Gills (personal communication, 1992) and Fichman⁶ address preexisting astigmatism by altering the incision's size (up to 5 mm) and location to the deepest corneal meridian to address preexisting astigmatism. David Brown (personal communication, 1992) operates from the temporal periphery but grooves the cornea and dissects the tunnel with metal blades, with results similar to my own. Kohnen and associates¹⁷ reported at the 1994 European Society of Cataract and Refractive Surgery in Lisbon, Portugal (September 19, 1994), similar surgically induced astigmatism with clear corneal cataract incisions.

CONCLUSIONS

The self-sealing corneal tunnel incision for phacoemulsification and foldable IOL implan-

tation is a new, systematic approach to cataract surgery. The initial results obtained by pioneering surgeons using this technique appear comparable to 3.2- to 4-mm scleral tunnel sutureless surgery in terms of the low level of induced astigmatism and early postoperative visual acuity. These results, along with the distinct advantages of this technique, help account for the expanding utilization of this technique.

Current areas of investigation include attempts at modifying the cartridge to allow for even smaller incisions compatible with downsized phacoemulsification tips, modifications and redesign of the diamond knife as other characteristics appear to have some advantage, documentation of changes with computerized corneal topography, and expanded clinical studies comparing results with the 3-mm incision to those obtained with 2.5- to 2.6-mm incisions.

This new systematized approach to cataract surgery offers many benefits, not only in reduced surgical time and costs but also in enhanced patient outcomes. I believe that this will become a new standard of care and will convert most cataract surgeons to foldable IOL technology.

References

1. Arnott EJ: Intraocular implants. *Trans Ophthalmol Soc UK* 101:58-60, 1981
2. Brown DC, Fine IH, Gills JP, et al: The future of foldable IOLs [symposia, moderated by DR Sanders]. *Ocul Surgery News* August 15(suppl):1992
3. Cravy TV: Routine use of the lateral approach to cataract extraction to achieve rapid and sustained stabilization of postoperative astigmatism. *J Cataract Refract Surg* 17:415-423, 1991

4. Ernest PH: The self-sealing sutureless wound: Engineering aspects with experimental studies. *In* Gills JP, Martin RG, Sanders DR (eds): Sutureless Cataract Surgery. Thorofare, NJ, Slack, 1993, pp 23-39
5. Fichman RA: Phacoemulsification with topical anesthesia. *In* Fine IH, Fichman RA, Grabow HB (eds): Clear-corneal cataract surgery and topical anesthesia. Thorofare, NJ, Slack, 1993, pp 114-118
6. Fichman RA: The clear corneal incision and astigmatism strategies. *In* Fine IH, Fichman RA, Grabow HB (eds): Clear-corneal cataract surgery and topical anesthesia. Thorofare, NJ, Slack, 1993, pp 72-76
7. Fine IH: Architecture and construction of a self-sealing incision for cataract surgery. *J Cataract Refract Surg* 17(suppl):672-676, 1991
8. Fine IH: Corneal tunnel incision with a temporal approach. *In* Fine IH, Fichman RA, Grabow HB (eds): Clear-corneal cataract surgery and topical anesthesia. Thorofare, NJ, Slack, 1993, pp 25-26
9. Fine IH: Cortical cleaving hydrodissection. *J Cataract Refract Surg* 18:508-512, 1992
10. Fine IH: Uma incisao para a Facu. *Oftalmologia* 9: 1-12, 1992
11. Fine IH, Lewis JS: New techniques and instruments for lens implantation. *Current Opinion in Ophthalmology* 1995, in press
12. Fine IH, Maloney WF, Dillman DM: Crack and flip phacoemulsification. *J Cataract Refract Surg* 19: 797-802, 1993
13. Galand A: La technique de l'enveloppe. Liege, Belgium, Pierre Mardaga, 1988
14. Grabow HB: The clear corneal incision. *In* Fine IH, Fichman RA, Grabow HB (eds): Clear-corneal cataract surgery and topical anesthesia. Thorofare, NJ, Slack, 1993, pp 55-58
15. Harms H, Mackensen G: Intracapsular extraction with a corneal incision using the Graefe knife. *In* Ocular surgery under the microscope. Stuttgart, Germany, Georg Thieme-Verlag, 1967, pp 144-153
16. Kelman CD: Phacoemulsification and aspiration: A new technique of cataract removal. A preliminary report. *Am J Ophthalmol* 64:23, 1967
17. Kohnen T, Dick B, Jacobi KW: Comparison of the induced astigmatism after clear corneal tunnel incision of different sizes. *J Cataract Refract Surg* 1995, in press
18. Martin RG, Sanders DR, Miller JD, et al: Effect of cataract wound incision size on acute changes in corneal topography. *J Cataract Refract Surg* 19(suppl):170-177, 1993
19. Paton D, Troutman R, Ryan S: Present trends in incision and closure of the cataract wound. *Highlights of Ophthalmology* 14:176, 1973
20. Sanders DR, Grabow HB, Ernest PH, et al: Visual and refractive results of sutureless IOL surgery. *In* Gills JP, Martin RG, Sanders DR (eds): Sutureless Cataract Surgery. Thorofare, NJ, Slack, 1992, pp 91-117
21. Shepherd JR: Induced astigmatism in small incision cataract surgery. *J Cataract Refract Surg* 15:85-88, 1989
22. Shimizu K: Pure corneal incision. *Phaco Foldables* 5:6-8, 1992
23. Williamson CH: Cataract keratotomy surgery. *In* Fine IH, Fichman RA, Grabow HB (eds): Clear-corneal cataract surgery and topical anesthesia. Thorofare, NJ, Slack, 1993, p 87
24. Williamson CH: Topical anesthesia using lidocaine. *In* Fine IH, Fichman RA, Grabow HB (eds): Clear-corneal cataract surgery and topical anesthesia. Thorofare, NJ, Slack, 1993, pp 121-128

Address reprint requests to

I. Howard Fine, MD
Oregon Health Sciences University
1550 Oak St., Suite 5
Eugene, OR 97401