
Bimanual bipolar diathermy for recurrent hyphema after anterior segment intraocular surgery

I. Howard Fine, MD, Richard S. Hoffman, MD, Mark Packer, MD

Phacoemulsification with mechanical pupil dilation was performed on a functionally monocular glaucoma patient with pseudoexfoliation syndrome. The postoperative course was complicated by persistent intraocular hemorrhaging from the pupil margin in multiple locations that ceased temporarily with a marked elevation in intraocular pressure (IOP). Normalization of IOP with medication or paracentesis resulted in recurrent bleeding and a subsequent increase in IOP elevation. Surgical intervention using bipolar diathermy was required to control the bleeding and the elevated IOP. A bimanual approach allowed the corrective procedure to be performed in a simple and efficacious manner.

J Cataract Refract Surg 2004; 30:2017–2020 © 2004 ASCRS and ESCRS

Hemorrhages within the anterior chamber (AC) during anterior segment surgery are infrequent and usually benign complications of intraocular surgery. Bleeding is usually self-limiting, and moderate hyphemas will resolve without permanent sequelae if the increased intraocular pressure (IOP) is controlled. Rarely, intraocular bleeding results in uncontrolled IOP elevations that require intervention. We present a case of unremitting intraocular hemorrhaging in a functionally monocular glaucoma patient that resolved with the use of intraocular bipolar diathermy. The use of a bimanual technique allowed the procedure to be performed in a straightforward and efficacious manner.

Case Report

The patient was a 81-year-old white woman with pseudoexfoliation syndrome (PXE) and moderately advanced glaucoma. The cup-to-disc ratio was 0.6 in the right eye and

0.7 in the left eye. The patient's pupils dilated poorly, and she had advanced nuclear sclerotic cataracts with a visual acuity of 20/100 in the eye with better vision.

Six months before the patient was evaluated in our clinic, phacoemulsification was performed in the left eye by an experienced cataract surgeon. The surgery was complicated by zonular dialysis toward the end of the procedure that required a limited anterior vitrectomy. The postoperative course was complicated by intense sterile anterior segment inflammation, a rhegmatogenous retinal detachment (RD) requiring a scleral buckle, intractable glaucoma treated with a filtering procedure, and a second RD with a second scleral buckle. The final outcome in the left eye was a visual acuity of counting fingers (CF) temporally.

Phacoemulsification in the right eye was performed under topical anesthesia (I.H.F.). Poor pupil dilation was addressed with a 2-prong Bechler pupil dilator (19009/2.8, Moria). Multiple small hemorrhages were noted around the pupil margin (Figure 1) but did not appear unusual in an iris stretched with this device. The presence of PXE in both eyes and the history of zonular dialysis in the first eye prompted the use of a capsular tension ring (CTR). After a capsulorhexis was formed, the CTR (Morchor GmbH) was injected into the capsular bag and phacoemulsification and intraocular lens implantation were completed uneventfully. At the end of the procedure, 0.5 cc of carbachol (Carbistat®) was injected into the AC and stromal hydration of the incisions performed. A few red blood cells were noted in the AC, but no active bleeding was observed.

The patient's advanced glaucoma and monocular status required close follow-up. One hour after surgery, the IOP was 10 mm Hg and the visual acuity was 20/200 secondary to a small amount of scattered blood in the AC. The next

Accepted for publication January 12, 2004.

From a private practice, Eugene, Oregon, USA.

Presented at the ASCRS Symposium on Cataract, IOL and Refractive Surgery, San Francisco, California, USA, April 2003.

None of the authors has a financial or proprietary interest in any material or method mentioned.

Reprint requests to Richard S. Hoffman, MD, 1550 Oak Street, Suite 5, Eugene, Oregon 97401, USA. E-mail: rshoffman@finemd.com.

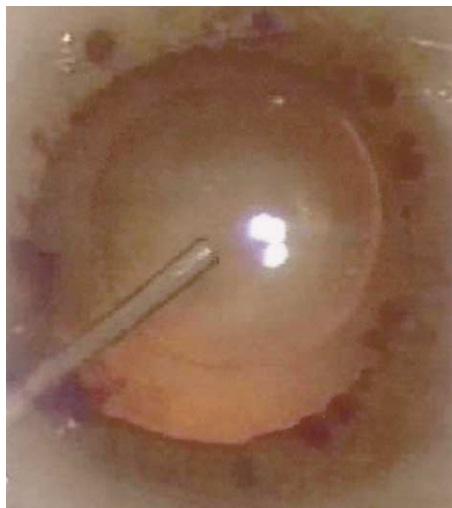

Figure 1. (Fine) Multiple pinpoint sites of hemorrhaging around the pupil margin after pupil stretching.

day, the patient had a visual acuity of hand motions (HM), a 10% hyphema, and an IOP of 42 mm Hg in the right eye. Aqueous was released by depressing the posterior lip of the paracentesis. This successfully lowered the IOP to 16 mm Hg but resulted in immediate profuse hemorrhaging from the pupil margin (Figure 2). Two hours later, the visual acuity was CF. The patient had a 10% hyphema with no active bleeding, but the IOP was again elevated to 41 mm Hg. One drop of brimonidine tartrate (Alphagan-P®) and 1 drop of timolol and dorzolamide (Cosopt®) were administered. Four hours later, the IOP had decreased to 16 mm Hg, with a subsequent rebleed from the pupil margin and decreased visual acuity to HM. No additional glaucoma medication was prescribed.

On day 2, the patient returned with a 20% hyphema and an IOP of 39 mm Hg. The patient's trepidation and the surgeon's concern for potential irreversible vascular events

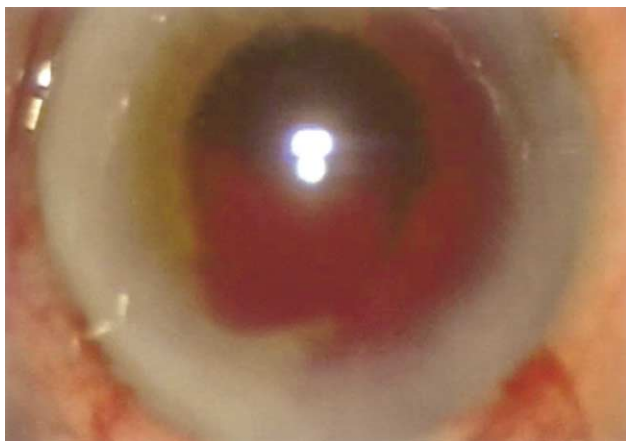


Figure 2. (Fine) Profuse bleeding from the pupil margin after paracentesis and lowered IOP.

or glaucomatous damage prompted surgical intervention. A surgical solution seemed necessary because hemorrhaging appeared to cease only in the presence of marked IOP elevation, a condition undesirable in a monocular patient with significant glaucomatous optic nerve damage.

The patient had no history of a bleeding diathesis and was not taking blood thinners or anticoagulants. A hematologic workup was thought to be unproductive and was not performed.

Surgical Technique

The same day, the patient was taken to the OR to control the bleeding with bipolar diathermy (I.H.F.). The original paracentesis at 10 o'clock was opened, and the subsequent lowered IOP resulted in rebleeding from the pupil margin. Sodium hyaluronate 3.0%–sodium chondroitin sulfate 4.0% (Viscoat®) was injected into the AC followed by a second 1.2 mm incision at 7 o'clock. These microincisions allowed a bimanual approach to the AC. Irrigation was accomplished with a 20-gauge bimanual irrigating cannula (Microsurgical Technology), and bipolar diathermy was administered with a bipolar 23-gauge Mentor Wetfield Hemostatic Eraser with a needlepoint tip (22-1266, Medtronic Solan) (Figure 3). With the insulating sleeves on these bipolar needles, all diathermy energy was localized to the tip, avoiding the possibility of corneal wound burns. The diathermy unit was an ASSI Polar-Mate (Accurate Surgical & Scientific Instruments Corp.) set at an output level of 1-2.

The irrigating cannula cleared blood from the AC, allowing an unobstructed view of the iris and pupil

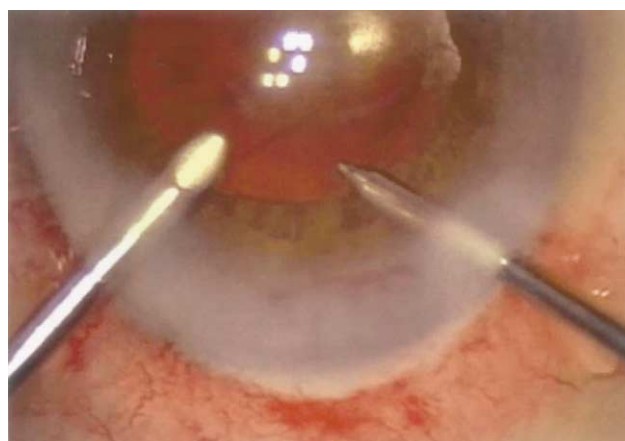


Figure 3. (Fine) Bimanual bipolar diathermy instrumentation: a 20-gauge irrigating cannula (left) and bipolar diathermy (right).

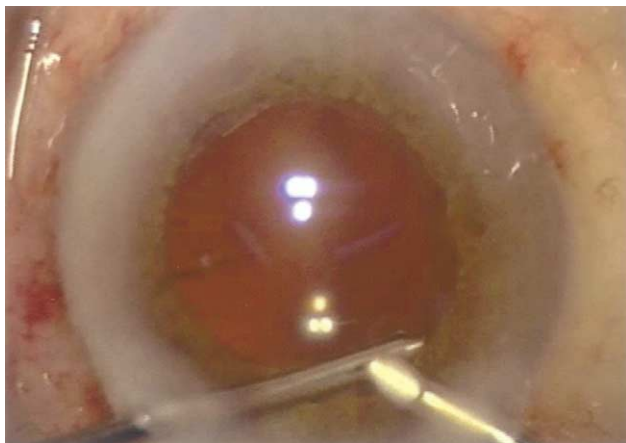


Figure 4. (Fine) Exchange of irrigation and diathermy instruments between microincisions to gain access to subincisional hemorrhage site.

margin. Attempts to achieve hemostasis by applying diathermy to the anterior surface of the pupil margin overlying active sites of bleeding were unsuccessful. The bleeding appeared to emanate from the posterior surface of the iris, 0.5 mm from the margin. Ultimately, placing the diathermy tip behind the iris and lifting it slightly to avoid damaging the capsulorhexis with diathermy was successful in achieving hemostasis. Multiple hemorrhaging sites around the pupil margin were present. These were identified and treated by the surgical assistant pinching the infusion tubing intermittently. The lowered IOP resulted in active bleeding from these sites, allowing the primary surgeon to pinpoint regions for diathermy placement. Resuming infusion helped clear the blood from the AC when excessive blood obscured visualization. Switching the infusion cannula and diathermy instrument between the bimanual incisions allowed easy access to 360 degrees of the pupil margin (Figure 4). With this systematic approach, multiple areas of bleeding were identified and complete hemostasis was achieved.

Immediately after surgery, the patient was evaluated; the visual acuity was 20/70, the IOP was 23 mm Hg, and there were no signs of active bleeding. The next day, the uncorrected visual acuity (UCVA) was 20/60 with no active bleeding. One week later, the UCVA was 20/40 with no blood in the AC and an IOP of 26 mm Hg on brimonidine (Alphagan®) 3 times a day and Cosopt twice a day.

Discussion

Bipolar diathermy incorporates the passage of high-frequency alternating currents between 2 electrodes combined in the tip of 1 instrument. Focal concentration of the current creates heat that can be used for tissue cutting or coagulation. The use of bipolar diathermy to treat intraocular hemorrhaging within the anterior segment is not a new concept. Bipolar microcautery has been used successfully to treat bleeding from the AC angle and the ciliary body.^{1,2} Animal studies demonstrate that low doses of microcautery can be applied to the iris without inciting postoperative inflammation or significant pathology.³ Under most circumstances, hyphemas are self-limiting and resolve without permanent consequences, avoiding the need for surgical intervention. However, when bleeding is severe, recurrent, or contributes to uncontrolled IOP elevation in an already compromised glaucomatous eye, diathermy may be useful and necessary.

This case was unusual in that bleeding from the iris microsphincterotomy (created by pupil stretching) would only cease after the IOP became elevated. When the IOP was lowered with medications or paracentesis, profuse bleeding followed by a marked elevation in IOP and subsequent pressure-sensitive hemostasis ensued. The monocular nature of this patient and moderately advanced glaucomatous damage in the surgical eye made observation a poor treatment option. This was especially true because the patient demanded rapid visual recovery, fearing that her only useful eye was experiencing the same sequence of events as the first eye.

The bimanual approach to this case was unique in that it allowed the surgeon to accurately and effectively identify and treat each site of bleeding along the iris. Although irrigation from the infusion cannula stabilized the AC and cleared blood from the iris, it also temporarily created pressure-sensitive hemostasis, making recognition of the bleeding sites difficult. By intermittently pinching the infusion tubing, the AC was allowed to collapse slightly, lowering the IOP and restarting the microscopic bleeding. The site of hemorrhaging was then treated with bipolar diathermy. With several courses of clearing, induced bleeding, and diathermy, multiple areas of bleeding were distinguished and treated. The bimanual approach also allowed the entire pupil circumference to be accessed, which was especially important

since the diathermy probe tip had to be placed behind the pupil margin to successfully achieve permanent hemostasis.

Treating anterior segment bleeding in this manner also allows the surgeon to achieve hemostasis or prevent primary hemorrhaging in other surgical situations. Bleeding from the AC angle can be treated using a bimanual approach with an assistant holding a gonioscopy mirror for accurate diathermy placement. Neovascularization of the iris can also be treated before creating an iridectomy⁴ or before pupil stretching in a cataract case to avoid the creation of a hyphema. In high-risk patients, such as those on anticoagulants or eyes with advanced glaucoma, intraocular bleeding can be treated during the primary surgery rather than allowing the possibility of recurrent, uncontrolled postoperative hyphema and uncontrolled glaucoma.

We believe the use of bimanual bipolar diathermy for primary intraoperative or postoperative hyphema is simple and efficacious and may prevent serious morbidity in susceptible patients.

References

1. Michels RG, Rice TA. Bimanual bipolar diathermy for treatment of bleeding from the anterior chamber angle. *Am J Ophthalmol* 1977; 84:873–874
2. Gilbert HD, Smith RE. Traumatic hyphema: treatment of secondary hemorrhage with cyclodiathermy. *Ophthalmic Surg* 1976; 7(3):31–35
3. Kass MA, Hersh SB, Albert DM. Experimental iridectomy with bipolar microcautery. *Am J Ophthalmol* 1976; 81:451–454
4. Hersh SB, Kass MA. Iridectomy in rubeosis iridis. *Ophthalmic Surg* 1976; 7(1):19–21