

Architecture of Clear Corneal Incisions Demonstrated by Optical Coherence Tomography (OCT)

I. Howard Fine, MD
Richard S. Hoffman, MD
Mark Packer, MD, FACS
The Oregon Eye Institute
Eugene, OR (U.S.A.)

I. Howard Fine, MD



The role of unsutured clear corneal incisions for cataract surgery in the apparent increased incidence of post-operative endophthalmitis is under intense scrutiny and the literature is not conclusive.²⁻⁹

Clear corneal incisions, which involve an incision in the plane of the cornea with a length equal to 2.0mm, were first described in 1992¹⁰ and we continue to construct them in essentially the same manner in our practice. In 1992, the incisions were as wide as 4.0mm, but more recently the maximum width is 3.5 – 3.8mm, if not sutured. **Figure 1** shows an artist's view of what the profile of clear corneal incisions were thought to look like. Part A shows the single plane incision and its apparent inherent lack of stability as one surface can easily slide over another. Charles Williamson, MD, from Baton Rouge, innovated an alteration of that incision which involves a shallow, perpendicular groove prior to incising the cornea into the anterior chamber (Part B). David Langerman, MD, deepened the perpendicular groove with the belief that it lead to greater stability (Part C). These grooved incisions have been abandoned by the authors in favor of a paracentesis-style incision due to gaping of the groove and the difficulties associated with persistent foreign body sensation and the pooling of mucus and debris in the gaping groove. More importantly, the grooved incisions represent a disruption in the fluid barrier that intact epithelium creates, which allows for a vacuum seal as a result of endothelial pumping.

That artist's view of these incisions has perpetuated until today, as we see in **Figure 2**¹¹, which has a similar architecture to the drawing in **Figure 1**, with the explanation of how these incisions open as a result of hypotony. In actual fact, since pressure within a fluid acts perpendicular to all surfaces, there would be a greater amount of pressure lifting the roof of the incision off the floor of the incision under conditions of eye pressure than the smaller area against which intraocular pressure would be pushing to help close the incision. However, as we will see, this view of the incision architecture is erroneous, with respect to our clear corneal incisions.

The initial incision construction technique began with a blade appanated to the surface of the globe, with the point at the edge of the clear cornea; the blade advanced for 2.0mm into the cornea before incising Descemet's membrane (**Figure 3**). These early incisions were made with knives with straight sides; however, these were subsequently replaced by trapezoidal-shaped knives in order to be able to enlarge the incision without violating the

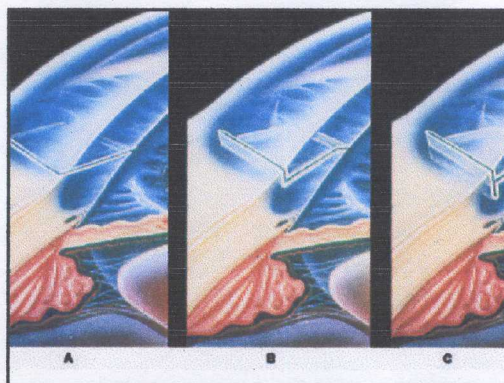


Figure 1:
Artist's interpretation of cross section view of clear corneal incisions circa 1992.

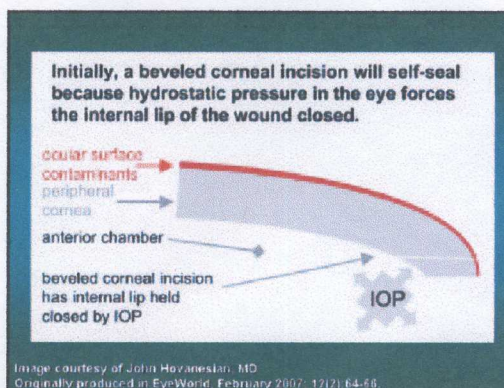


Figure 2:
Another artistic interpretation of cross section view of clear corneal incisions.

Image courtesy of John Hovanesian, MD
Originally produced in EyeWorld, February 2007, 12(2): 64-66

architecture by cutting sideways. From the onset of the use of clear corneal incisions, stromal hydration of the incisions, which thickens the cornea, forcing the roof of the incision onto the floor of the incision and facilitating endothelial pumping to the upper reaches of the cornea, was strongly advocated. Testing the seal of the incision with a Seidel test using fluorescein was also strongly advocated. These practices have not changed since 1992, except for eliminating the depression of the posterior lip of the incision.

We examined the profile of clear corneal incisions using the Zeiss Visante Optical Coherence Tomography (OCT) anterior segment imaging system. This technology has allowed the first view of the clear corneal incision in the living eye in the early post-operative period. All previous views were in autopsy eyes sectioned through the incision, which introduces artifacts. **Figure 4** shows an example of the corneal periphery in a control eye which includes the anterior chamber angle. The regularity of the corneal

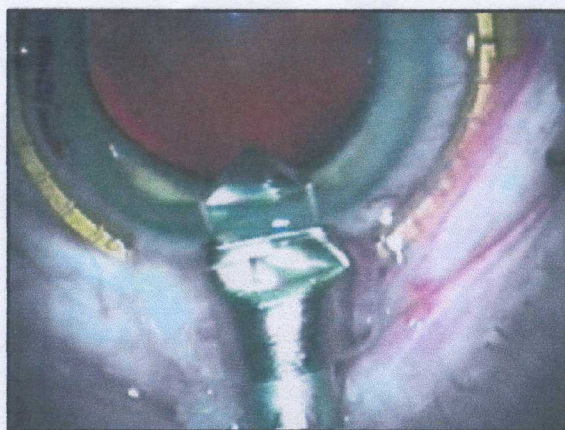


Figure 3: Clear corneal incision construction, circa 1992, with the blade completely inserted.

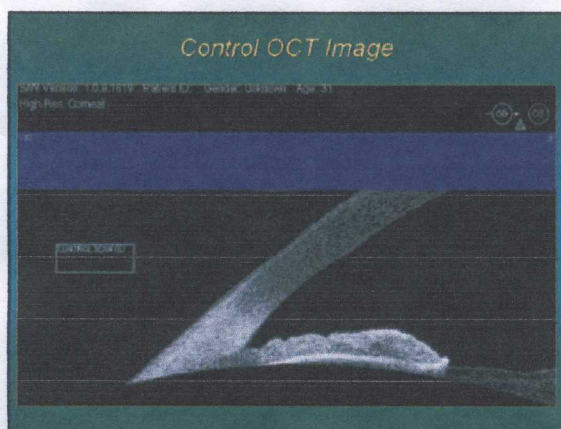


Figure 4: OCT image of a control eye showing the corneal periphery including the anterior chamber angle.

epithelium blending in the conjunctiva and the clear corneal stroma blending into sclera can be clearly seen.


All clear corneal incisions were made by one surgeon (IHF). The OCT images of each operative eye were taken on the first post-operative day, within 24 hours of cataract surgery, and are representative of multiple images from multiple patients. Incision width is defined as the measurement parallel to the limbus. Incision length is the distance, in a straight line, between the external incision and the entrance through Descemet's membrane. Several types of knives were used to create the clear corneal incisions during cataract surgery.

Figures 5 through 13, which were taken on the first day post-operatively, show that clear corneal incisions constructed in the way we described are actually curvilinear, not a straight line as seen in the artists' depictions. It is an arcuate incision with an arc length which is considerably longer than the chord length originally estimated for the length of the incision. It is very important to note that the architecture of the incision allows for a fit not unlike tongue and groove paneling, which adds a measure of stability to these incisions and makes sliding of one surface over the other considerably less likely.



CO-MICS

Goodbye to bimanual phaco!



You'll be convinced straightaway. Oertli® CO-MICS technology makes bimanual phaco a thing of the past. And what's more, Oertli® CO-MICS technology offers advantages over standard phaco systems. The chamber stability is unique and wound closure is perfect.


Why is that?

The flexible CO-MICS sleeve fits gently with the corneal **1.6 mm incision** and enables significantly more flow than bimanual choppers. It guarantees a perfect seal and eliminates out-flow from the wound. The small lumen of the CO-MICS tip creates high flow resistance and reduces the pressure drop significantly when the occlusion is broken. This avoids collapse.

Benefit from the advantages of CO-MICS technology!

- Normal, standard coaxial technique with 1.6 mm incisions
- New level of chamber stability, better than bimanual and standard coaxial systems
- Very high vacuum settings for maximum holding force and efficient emulsification
- Penetrates more easily into hard cores and enables safe ab-interno cracking
- No wound leakage during and after the operation
- Better visual monitoring with small pupils
- Optimal wound protection, even without cool-phaco setting

Oertli® CO-MICS technology is available with all OS3 and CataRhex®SwissTech machines. CO-MICS products are delivered in a sterile pack for one-time use.



oertli
SWITZERLAND

Oertli Instrumente AG, CH-9442 Berneck, Switzerland
Phone +41 (0)71 747 42 00, Fax +41 (0)71 747 42 90
www.oertli-instruments.com, info@oertli-instruments.com

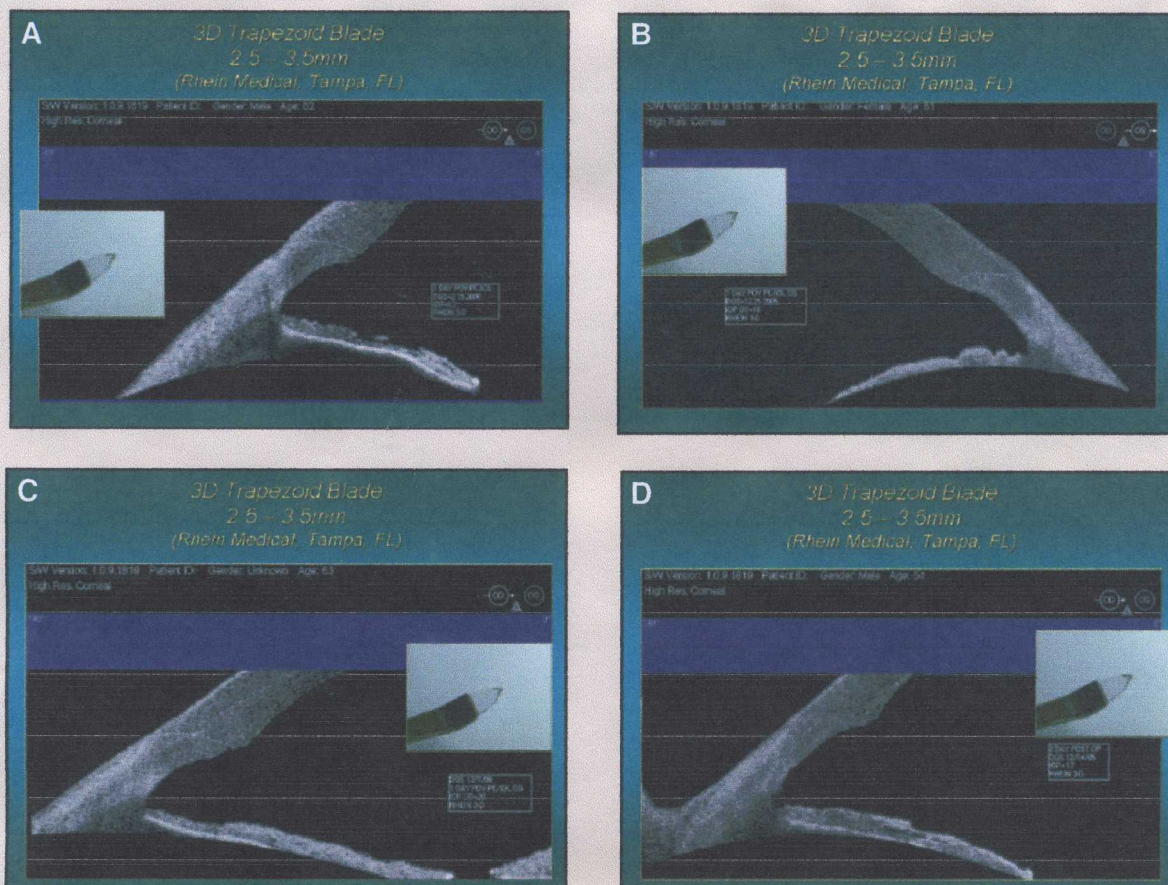


Figure 5 (A - D): OCT images of clear corneal incisions made with the Rhein 3D Trapezoidal 2.5 - 3.5 mm Blade. Image of the blade is inset.

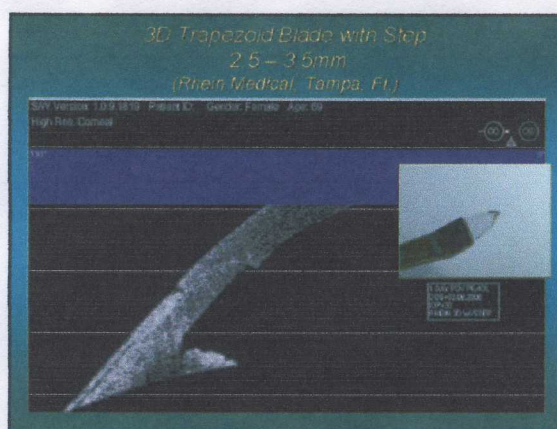


Figure 6: OCT image of a clear corneal incision with a 300° groove at the external edge of the incision. Image of the Rhein 3D blade is inset.




Figure 7: OCT image of clear corneal incision with the Accutome Simplicity 2.5-3.5mm Blade. Image of the blade is inset.

All clear corneal incisions demonstrated a similar, arcuate architecture, even though they were constructed using a variety of blades. **Figures 5 and 6** show clear corneal incisions made with the Rhein 3D Trapezoidal blade (#05-5088, Rhein Medical, Tampa FL). The BD Kojo Slit (BD Medical-Ophthalmic Systems, Franklin

Lakes, NJ, #372032) is a metal blade that is curved in the direction of the width of the incision. This creates an arcuate incision paralleling the curvature of the peripheral cornea with a chord length whose width is considerably smaller than the arcuate incision in the dimension tangential to the limbus itself, which may add a greater degree




Figure 8: OCT image of clear corneal incision with the Accutome Black 2.5-3.5mm Blade. Image of the blade is inset.




Figure 9: OCT image of clear corneal incision with the ASICO Clear Cornea Fixed Angle 2.5-2.8mm Blade. Image of the blade is inset.



Figure 10: OCT image of clear corneal incision with the Mastel Superstealth 2.4-3.0mm Blade. Image of the blade is inset.




Figure 11: OCT image of a clear corneal incision made with the BD Kojo 3.2mm Slit Blade. Image of blade is inset.




Figure 12: OCT image of a clear corneal incision made with an Alcon 2.2mm Metal Blade. Image of blade is inset.




Figure 13: OCT image of a clear corneal incision made with a BD Atomic Edge Metal Blade. Image of blade is inset.




Figure 14: OCT image of a clear corneal incision that did not receive stromal hydration.

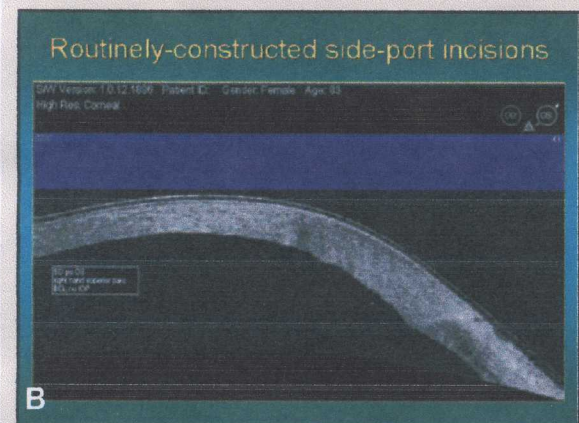
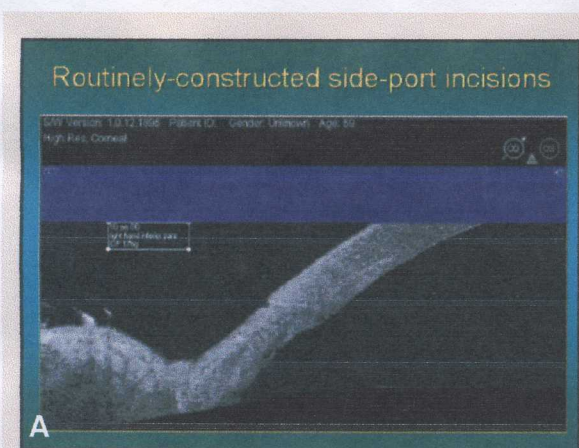


Figure 15 (A - B): OCT images of routinely-constructed side-port incisions. For Figure 15 (B), the bandage contact lens, which was applied due to an epithelial abrasion at the incision cite, is clearly visible.

of stability. Once again, the very advantageous architecture of the incision, as constructed by the BD blade, is observed in **Figure 11**. It is interesting to note once again that the arc length is considerably longer than the chord length and is probably a hyper-square incision in that it is only 2.0mm wide. Advantageous architecture can be achieved with any of the blades providing the construction of the incision is properly performed.

Figure 6 shows an incision that was made with a 300° groove at the external edge of the incision prior to incision construction. The incision itself has a curved or arcuate configuration, but the gaping of the external groove, which is noted on the first day post-operatively, is accompanied by a similar offset of the internal lips of the incision, which appears to be somewhat less stable than a paracentesis-style incision.

These images demonstrate the persistence of stromal swelling from stromal hydration on the first post-operative day, which many critics of clear corneal incisions believed disappeared within an hour or two. To confirm that the swelling is due to stromal hydration rather than surgical trauma, OCT images were taken of cases in which there was no stromal hydration of the incision. As demonstrated in **Figure 14**, which is representative of an incision which did not undergo stromal hydration, there is less thickening around the incision and some gaping of the internal lip of the incision.

Finally, each figure also has the intraocular pressure recorded at the time of the post-operative visit. Many of these are hypotonous and yet they are still perfectly well sealed, which contradicts current thinking regarding incision architecture and hypotony.¹¹

A surprising finding was that proper incision construction resulted in a longer incision than the chord length that was measured and in greater stability (like tongue in groove paneling) of the incision. Another surprising finding was that stromal swelling does indeed last for at least 24 hours. These findings demonstrate some of the characteristics that the authors believe have contributed to an added measure of safety in clear corneal incisions that, in conjunction with other prophylactic measures, can result in the absence of endophthalmitis.

Endophthalmitis prophylaxis involves a large number of factors including proper pre-operative antibiotic regime; preparation of the surgical field including Betadine and draping over the lashes and meibomian orifices; incision construction; surgical technique including atraumatic surgery; power modulations to avoid heating the incision; avoiding grasping the roof of the incision with a toothed forceps which would abrade the epithelium and disrupt the fluid barrier for endothelial pumping; incision closer; testing for leakage; and post-operative antibiotics. The authors have gone for longer than ten years and over 10,000 cases without a single case of infectious endophthalmitis.

Attention to all of the details for endophthalmitis prophylaxis is essential. However, incision construction leading to proper architecture is of primary importance among all of the variables that are part of endophthalmitis prophylaxis. This is the same conclusion that was made in a recent white paper by the American Society of Cataract and Refractive Surgery (ASCRS)¹³. It is important to recognize that all clear corneal incisions are clearly not the same.

An incision in the plane of the cornea with a chord length of at least 2mm appears to give uniquely advantageous architecture for adequate self-sealability.

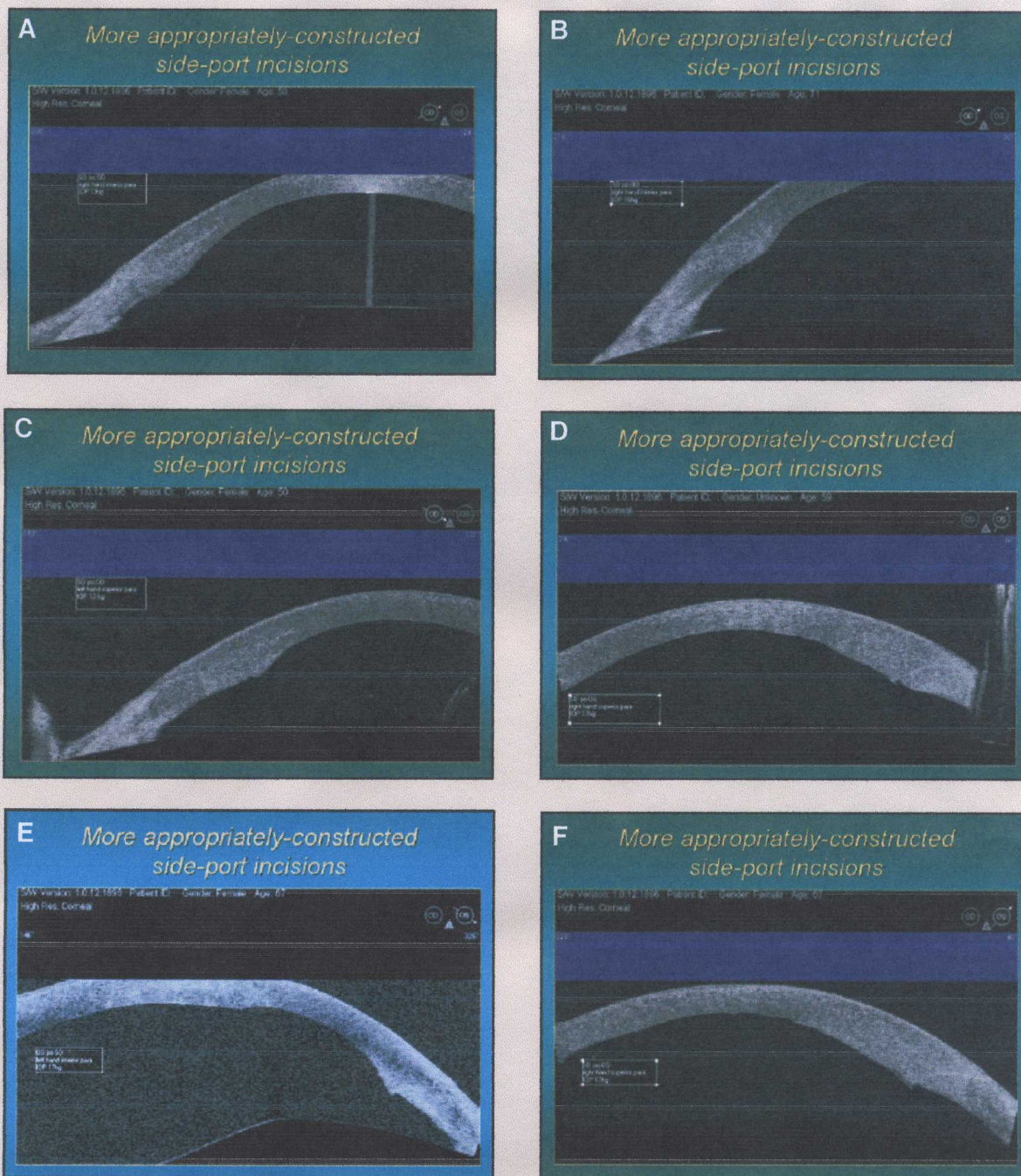


Figure 16 (A - F): OCT images of more appropriately-constructed side-port incisions.

Side Port Incisions

We have been doing bimanual microincision phacoemulsification for over six years and we have found that our side-port incisions, through which we use irrigating choppers in one hand and an unsleeved phacoemulsification needle in the other, to be a little more difficult to seal than we were used to with the coaxial

side-port incision. Attention has recently been directed towards possible damage to side-port incisions as a result of the use of an unsleeved phaco tip.¹⁴⁻¹⁷ It is important to note that these investigators have not completed a learning curve in bimanual microincision phacoemulsification and so some of what is demonstrated may be the result of their novice status with respect to this technique. However, as a result of our study of clear corneal cataract

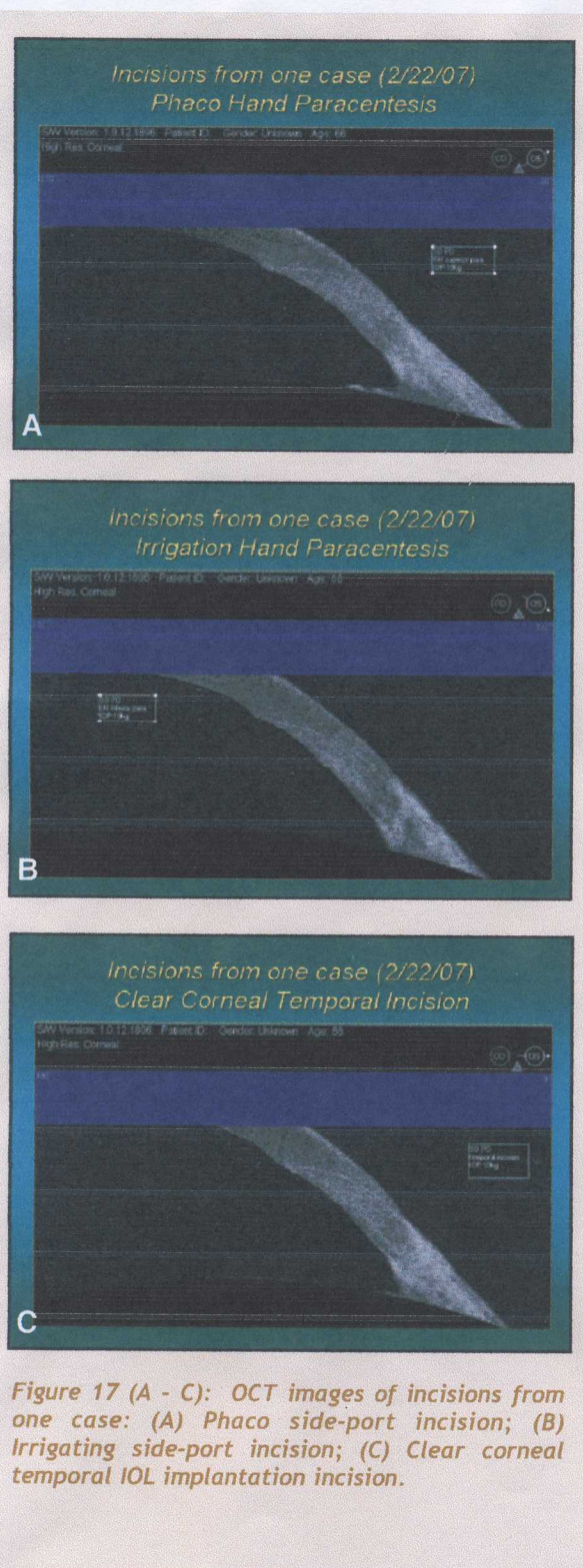


Figure 17 (A - C): OCT images of incisions from one case: (A) Phaco side-port incision; (B) Irrigating side-port incision; (C) Clear corneal temporal IOL implantation incision.

incisions, we decided to look at our side-port incisions and we were quite surprised to find that many of them did not contain the architecture that we prefer but were closer to the architecture demonstrated in the artist's depictions of clear corneal incisions (**Figures 15 A – B**).

As a result of our studying these incisions, we began to take the same amount of time, effort, and precision in side-port incision construction as we do in our larger incisions. In this way, by making incisions more carefully and longer, we were able to achieve exactly the same architecture in our side-port incisions (**Figures 16 A – F**). Each of these figures contain an incision location as depicted in the circle in the right-hand upper corner, where the bottom of the circle represents the temporal periphery and the meridian of the incision is located by the arrow as seen from the surgeon's perspective, sitting temporally. Within the box in the lower left-hand corner, we indicate for which hand the paracentesis was made. In each instance, all right hand incisions were the one through which the unsleeved phaco needle was placed, and all left-hand incisions were the ones through which the irrigating chopper was placed.

The last three figures (**Figures 17 A – C**) show a single case in which we had done a refractive lens exchange. We can see not only the beautiful architecture of the side-port incisions, which seal much more easily now that we have concentrated on incision construction with side-ports in the same way that we have with the larger, central incision. We can see the implantation incision, through which a Synchrony IOL was injected, was a self-sealing 3.8mm incision.

The examination of side-port incisions with OCT forces us to recognize that proper incision architecture for side-port incisions requires the same, appropriate incision construction as for temporal clear corneal incisions. The blade must be advanced in the plane of the cornea for an adequate length (approximately 1.5mm) before incising Descemet's membrane.

For most surgeons, the transition to clear corneal incisions also involved transition to temporal surgery. For right-handed, coaxial surgeons operating on left eyes, the side-port incision is in the inferior conjunctival cul-de-sac. The role of inferior side-port incisions in post-operative endophthalmitis has been raised. It would be interesting to review the literature showing an increased incidence of endophthalmitis to see if left eyes predominate.

Cataract surgery begins with incision construction. Proper incision architecture can be achieved through appropriate incision construction which requires an unfailing attention to detail for both temporal clear corneal and side-port incisions. ■

For detailed and complete References, please visit our "Journal Bibliography" Section at our webpage: www.thehighlights.com